

Original article

<https://doi.org/10.17816/2311-2905-17473>

## Femoral Malalignment Deformity Acute Correction and Gradual Limb-Lengthening by Bifocal Osteosynthesis with a Monorail External Fixator

Kunqi Zhang, Yifan Yu, Feng Wang, Hanzhe Zhang, Shanyu Li, Yuting Cao, Qinglin Kang, Jia Xu

Shanghai Sixth People's Hospital Affiliated to Shanghai Jiao Tong University School of Medicine, Shanghai, China

### Abstract

**Background.** Patients with limb-length discrepancies often present with concomitant distal femoral varus or valgus deformities. With the development of distraction osteogenesis, both deformity correction and limb-lengthening can be performed simultaneously. This novel procedure is being increasingly preferred not only by experts due to the technical advance it implies, but also by patients.

**The aim of this study** was to identify the clinical efficacy of distal femoral malalignment deformity correction and gradual limb-lengthening by bifocal osteotomies.

**Methods.** We analyzed 32 femurs from 30 patients (mean age — 23.8 years) who had undergone bifocal osteotomies followed by the use of the monorail external fixator to correct the distal femoral malalignment deformity acutely and limb-length discrepancy gradually from June 2012 to May 2020. Pre-operative clinical and radiographic data were also obtained. During the follow-up period, deformity correction and bone healing were assessed, complications were identified, and functional outcomes were evaluated.

**Results.** The mean follow-up period was 57.2 months for all the patients. The mean mechanical axis deviation improved from 66.4 mm pre-operatively to 7.5 mm. In patients with varus deformity, the mean mechanical lateral distal femoral angle (mLDFA) decreased from 121.2° pre-operatively to 90.2° after surgery; whereas in patients with valgus deformity, the mean mLDFA improved from 59.2 to 87.1°. The magnitude of lengthening achieved averaged 6.3 cm, and the mean bone healing index was 34.8 days/cm. The final scores defined by the Association for the Study and Application of the Methods of Ilizarov (ASAMI)-Paley were excellent in 93.3% of patients.

**Conclusions.** Acute correction of femoral deformities and gradual lengthening with a monorail external fixator following bifocal osteotomies can be used to treat femoral shortening and distal malalignment deformity. Functional and cosmetic improvements are expected after surgery and post-operative rehabilitation.

**Keywords:** bifocal osteosynthesis, deformity correction, femoral lengthening, monorail external fixator.

**Cite as:** Zhang K., Yu Y., Wang F., Zhang H., Li S., Cao Y., Kang Q., Xu J. Femoral Malalignment Deformity Acute Correction and Gradual Limb-Lengthening by Bifocal Osteosynthesis with a Monorail External Fixator. *Traumatology and Orthopedics of Russia*. <https://doi.org/10.17816/2311-2905-17473>.

✉ Jia Xu; e-mail: xujia0117@126.com

Submitted: 21.02.2024. Accepted: 19.08.2024. Published Online: 04.09.2024.

© Zhang K., Yu Y., Wang F., Zhang H., Li S., Cao Y., Kang Q., Xu J., 2024



Научная статья  
УДК 616.78.4-007.24-089.84  
<https://doi.org/10.17816/2311-2905-17473>

## Острая коррекция осевой деформации бедренной кости и постепенное удлинение нижней конечности методом бифокального остеосинтеза с использованием моностерального внешнего фиксатора

Куныци Чжан, Ифань Юй, Фэн Ван, Ханьчжэ Чжан, Шаньюй Ли, Юйтин Цао, Цинлинь Кан, Цзя Сюй

*Shanghai Sixth People's Hospital Affiliated to Shanghai Jiao Tong University School of Medicine, Shanghai, China*

### Реферат

**Введение.** Пациенты с неравной длиной нижних конечностей часто имеют сопутствующую варусную или вальгусную деформацию дистального отдела бедренной кости. Развитие дистракционного остеогенеза позволило одновременно выполнять коррекцию деформации и удлинение конечности. Этот передовой метод все чаще выбирают не только специалисты, но и сами пациенты.

**Целью исследования** было определить клиническую эффективность бифокальных остеотомий для коррекции деформации дистального отдела бедренной кости и постепенного удлинения конечности.

**Материал и методы.** Мы проанализировали результаты лечения 30 пациентов (32 бедренные кости) со средним возрастом 23,8 лет, которым с июня 2012 г. по май 2020 г. была проведена бифокальная остеотомия с последующим наложением моностерального внешнего фиксатора для острой коррекции осевой деформации дистального отдела бедренной кости и постепенного устранения разницы в длине конечностей. До операции были изучены клинические и рентгенологические данные. В послеоперационном периоде производилась оценка коррекции деформации, костного сращения и функциональных показателей, а также анализировались осложнения.

**Результаты.** Средний период наблюдения составил 57,2 мес. для всех пациентов. Отклонение механической оси в среднем уменьшилось с 66,4 мм до 7,5 мм. У пациентов с варусной деформацией среднее значение механического латерального дистального бедренного угла (МЛДБУ) уменьшилось с 121,2° до операции до 90,2° после операции. У пациентов с вальгусной деформацией среднее значение МЛДБУ увеличилось с 59,2 до 87,1°. Удлинение составило в среднем 6,3 см, а средний индекс излечения — 34,8 дня/см. Функциональные результаты лечения, определяемые в соответствии со шкалой Ассоциации по изучению и применению аппарата и метода Илизарова (Paley/ASAMI), были признаны отличными у 93,3% пациентов.

**Заключение.** Острая коррекция деформации бедренной кости и ее постепенное удлинение при помощи моностерального внешнего фиксатора после бифокальной остеотомии могут применяться для лечения укорочения и дистальной осевой деформацией бедренной кости. Хирургическое лечение данной патологии и послеоперационная реабилитация позволяют добиться хороших косметического эффекта и функциональных результатов.

**Ключевые слова:** бифокальный остеосинтез, коррекция деформации, удлинение бедренной кости, моностеральный внешний фиксатор.

**Для цитирования:** Чжан К., Юй И., Ван Ф., Чжан Х., Ли Ш., Цао Ю., Кан Ц., Сюй Ц. Острая коррекция осевой деформации бедренной кости и постепенное удлинение нижней конечности методом бифокального остеосинтеза с использованием моностерального внешнего фиксатора. *Травматология и ортопедия России*. (На англ.). <https://doi.org/10.17816/2311-2905-17473>.

Цзя Сюй; e-mail: xujia0117@126.com

Рукопись получена: 21.02.2024. Рукопись одобрена: 19.08.2024. Статья опубликована онлайн: 04.09.2024.

© Чжан К., Юй И., Ван Ф., Чжан Х., Ли Ш., Цао Ю., Кан Ц., Сюй Ц., 2024

## INTRODUCTION

The combined occurrence of distal femoral malalignment deformities (varus and valgus) with limb-length discrepancy can be caused by congenital anomalies, metabolic disorders, post-traumatic sequelae, and adolescent Blount's disease [1]. With the development of distraction osteogenesis, both deformity correction and limb-lengthening can be performed simultaneously. This novel procedure is being increasingly preferred not only by experts due to the technical advance it implies, but also by patients. In recent publications, circular external fixation, motorized intramedullary nailing followed by distal femoral locking plate, and fixator-assisted intramedullary nailing have been introduced as alternative methods to this procedure [2, 3, 4]. However, they present disadvantages. Circular apparatus is technically demanding, bulky, and uncomfortable owing to its size. A motorized intramedullary nail is appropriate for femoral lengthening [5], but its use is limited for the correction of concomitant malalignment deformities, which has to be performed with the assistance of other fixation methods. Moreover, motorized nailing is not currently available in the mainland of China.

We have found few reports describing the use of bifocal osteosynthesis to correct compound deformities using a monorail external fixator.

*The aim of this study* was to identify the clinical efficacy of distal femoral malalignment deformity correction and gradual limb-lengthening by bifocal osteotomies.

## METHODS

### Patients

The data of 30 patients (32 femurs), who presented distal femoral varus or valgus deformities and femoral shortening with an abnormal gait between June 2012 and May 2020, were retrospectively investigated. Symptoms and radiographs were reviewed to confirm whether patients complied with the indications for the procedure, which were a distal femoral varus or valgus deformity (quantified by a mechanical axis deviation (MAD) >15 mm) and ipsilateral femur shortening. The patients experienced impairment of functional activities and unsatisfactory cosmetic appearance.

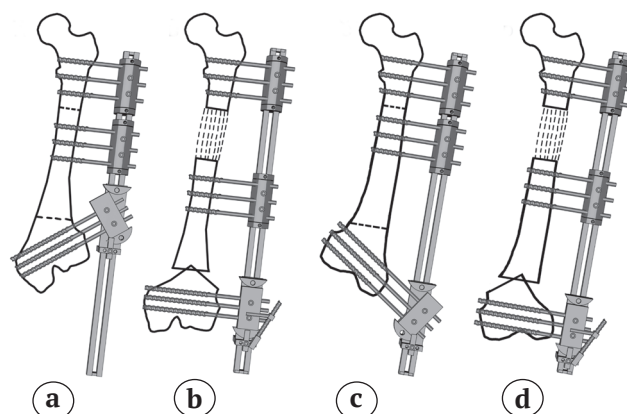
Pre-operatively, all patients were evaluated for malalignment deformities and limb-length discrepancy using standing radiographs of the lower extremities.

### Surgical technique

An appropriate length of the monorail external fixator equipped with one micrometric swiveling clamp (MSC) and two common clamps (Orthofix Srl, Italy), depending on the amount of femur shortening, was

prepared before the operation. The MSC addresses the angular deformity of the distal femur by aligning the half-pins in the plane of the desired correction. The surgery was performed under general anesthesia with the patient in a supine position on a radiolucent table. A tourniquet was not used in this study.

The true plane of the distal femoral deformity was identified using an image intensifier. The center of the metaphyseal osteotomy was planned at the level of the juxta-articular center of rotation of angulation (Figure 1).



**Figure 1.** Schematic diagrams of the surgical technique: a, c – the Micrometric Swiveling Clamp (MSC) was set to a desired angle from the axis of the rail, and the distal half-pins were inserted in the plane of varus or valgus deformity; b, d – distal deformity was corrected through the MSC, and lengthening was performed gradually through two proximal clamps

As the distal half-pins (diameter – 6.0 mm) had to be aligned with the plane of the deformity to enable correct functioning of the clamp, the fixator rail was applied in the same plane. The first distal half-pin was inserted through a screw guide mounted in the MSC, which was set to the desired angle based on the required correction. The second half-pin was implanted proximal to the lesser trochanter and perpendicular to the anatomical axis of the femur using the proximal clamp as reference. A distance of approximately 1.5–2.0 cm was maintained between the inner edge of the rail and the skin, while the adjacent clamps were separated from the proximal osteotomy level by approximately 5 cm. During insertion of the adjacent half-pins, proximal and distal skin retraction around the proximal osteotomy level was achieved. When the remaining half-pins were inserted, multiple transverse drill holes were made in the core of the distal deformity and in the femoral subtrochanteric region with a drill bit in a sleeve. Through these holes, two transverse osteotomies were performed with an

osteotome. The amount of angular correction and proper translation at the distal osteotomy site were determined pre-operatively and attained reliably with the MSC during the procedure. An image intensifier was used to confirm satisfactory angular correction and half-pins placement. Finally, the subtrochanteric osteotomy was left undisplaced, and the wounds were closed. The range of motion (ROM) was checked after the procedure, and an assessment of stability including varus and valgus stresses was performed.

### Post-operative care

Gauze dressings were used to compress the pin sites and were changed every 5-7 days. Mobilization, including physiotherapy with active and passive ROM exercises for the hip and knee, was started on the first post-operative day. The patients were encouraged to start standing and walking for at least 1 hour daily, with a shift from partial weight — bearing to full weight — bearing as soon as possible. Post-operative lengthening was started after seven days at a rate of 0.75 mm per day and continued with three increments (0.25 mm each time) until the desired amount of lengthening was achieved. All patients were reviewed every four weeks until the fixator was removed. Radiographs of the local bone and the entire limb length were periodically obtained to monitor the extent of distraction and consolidation. The half-pins could be removed by steps to promote callus formation during weight-bearing rehabilitation. Consolidation of the distraction area was considered sufficient when the formation of a bridging callus was obvious on three of the four visible cortices in the anteroposterior and lateral radiographs in patients who had no tenderness at the site of the osteotomy and no pain during full weight bearing without the connecting rail. After consolidation was confirmed, the fixator was removed in the outpatient clinic. Radiological parameters were recorded at the last follow-up visit.

### Statistical analysis

Statistical analysis was performed using IBM SPSS Statistics v. 22.0 (SPSS Inc., Chicago, IL, USA). Descriptive statistics were expressed as mean and range for continuous numerical variables, and as number for categorical variables.

## RESULTS

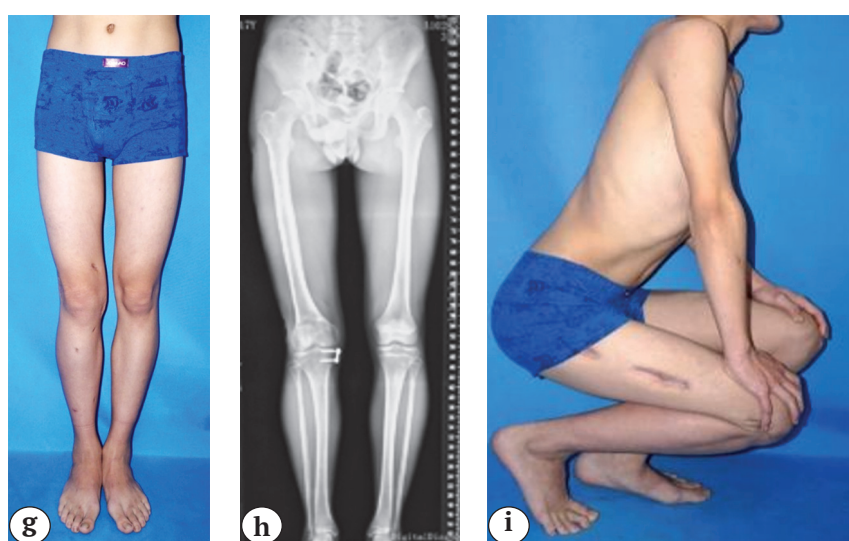
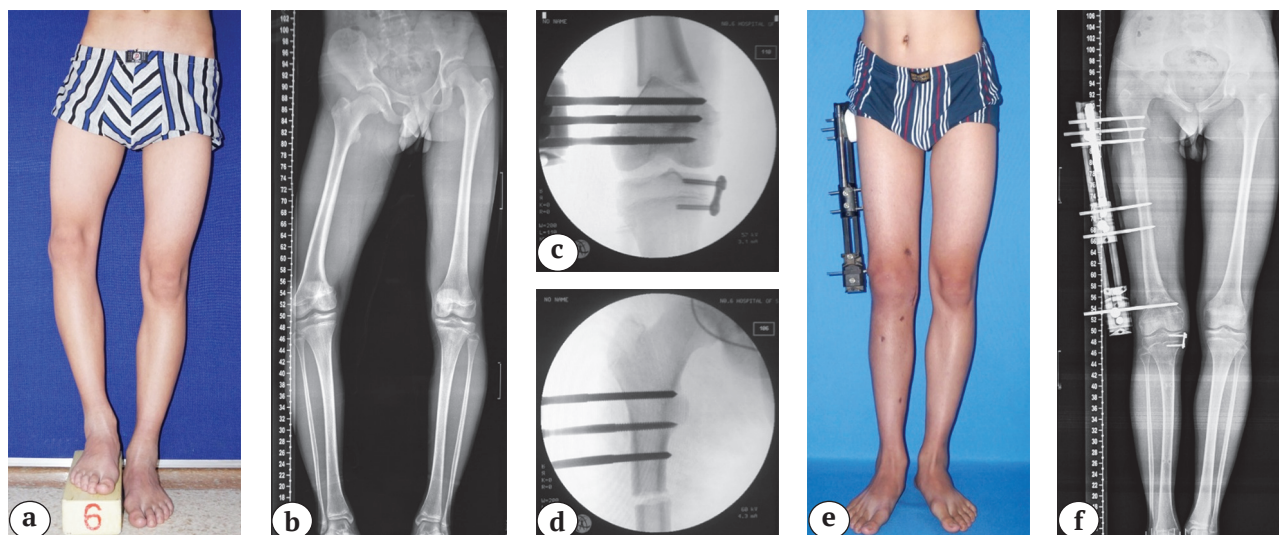
Out of the total of 30 patients, 17 were women and 13 were men. Their mean age was 23.8 years (16-42 years) at the time of surgery, which was performed after they had reached skeletal maturity (defined as the moment when the distal femoral growth plate is closed). The etiologies identified included congenital anomalies (11 cases), post-traumatic deformity and shortening (13 cases), hypophosphatemic rickets (2 cases), and poliomyelitic sequelae (4 cases).

The mean pre-operative MAD was 66.4 mm (28-122 mm). The mean mechanical lateral distal femoral angle (mLDFA) was 121.2° (100-136°) in patients with varus deformity (17 femurs in 16 patients), and 59.2° (44-74°) in patients with valgus deformity (15 femurs in 14 patients). The mean limb-length discrepancy was 6.9 cm (3-13 cm).

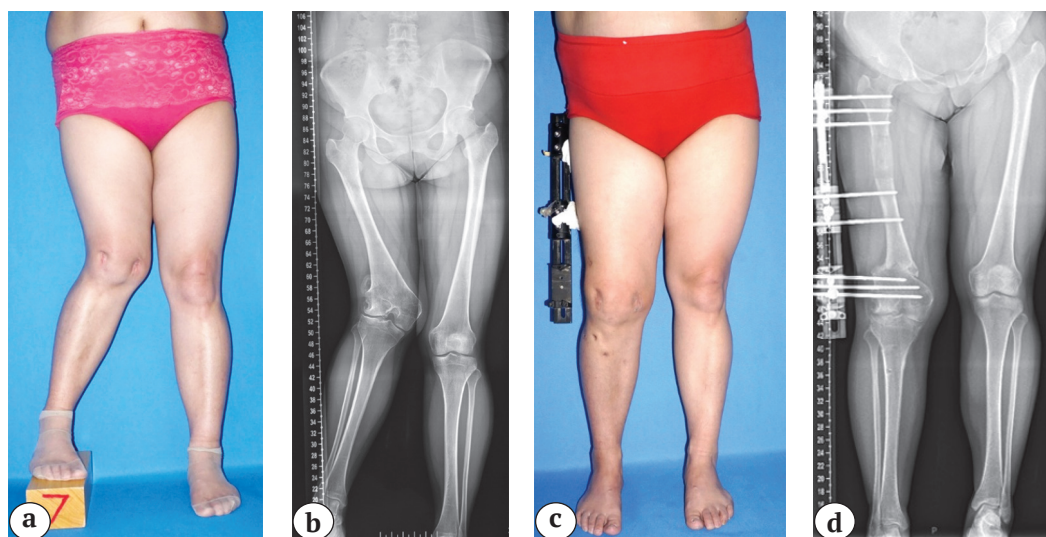
Satisfactory follow-up was provided to all patients, with a mean duration of 57.2 months (24-112 months). The mean MAD of the lower extremity improved from 66.4 mm (28-122 mm) before treatment to 7.5 mm (0-25 mm) after treatment. The mean post-operative mLDFA was 90.2° (85-100°) in patients with varus deformity, and 87.1° (80-92°) in patients with valgus. Healing of the distal osteotomy site was completed within an average period of 13.7 weeks (10-18 weeks). The mean limb-length discrepancy after treatment was 0.4 cm (0-3 cm). The size of lengthening achieved averaged 6.3 cm (range from 3 to 11 cm), and the mean bone healing index was 34.8 days/cm (range from 25.0 to 50.7 days/cm).

At the last follow-up visit, all affected knees had full extension, while the mean flexion was 126.9° (105-140°) and 132.2° (110-140°) pre-operatively. Owing to the intensive rehabilitation plan, there was no evidence of knee flexion contractures in our patients (Figure 2, 3). The functional score, as rated by the Association for the Study and Application of the Methods of Ilizarov (ASAMI)-Paley system [6], was excellent in 28 patients and good in 2. Five patients with a high body mass index had a superficial pin-track infection that responded well to local wound care until the pins were removed. No patients had fractures, external fixator breakage, or insufficient regeneration of bone. All patients reported that they could walk satisfactorily without pain after the procedure and that they were satisfied with their cosmetic and functional outcomes.

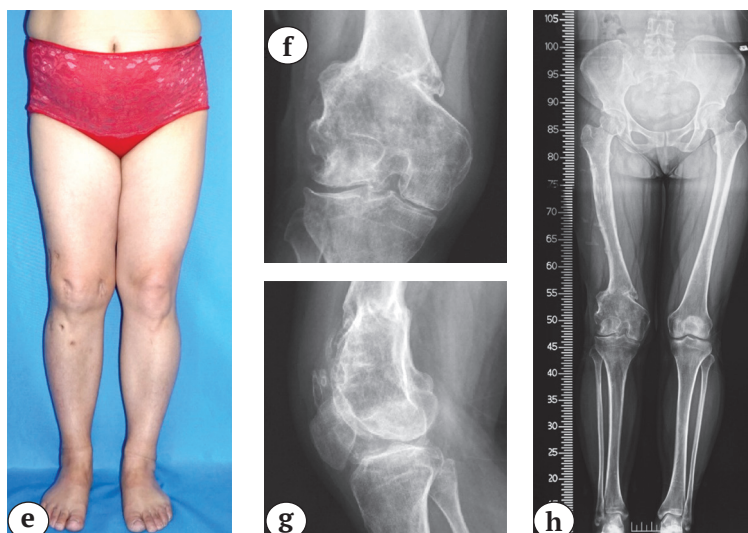




**Figure 2.** A 17-year-old boy with right femoral shortening of 6 cm and distal varus deformity:  
 a, b – before treatment;  
 c, d – intra-operative fluoroscopic images showed acute distal femoral deformity correction and gradual lengthening;  
 e, f – the consolidation phase after femoral malalignment correction and lengthening was confirmed by photography and radiography;  
 g, h, i – photographs and a radiograph evidenced that ideal cosmetic appearance and functional improvement were obtained



**Figure 3 (a, b, c, d).** A 40-year-old woman with right femoral shortening of 7 cm and distal valgus deformity:  
 a, b – before treatment;  
 c, d – the consolidation phase after distal femoral malalignment correction and proximal lengthening was confirmed by photography and radiography



**Figure 3 (e, f, g, h).** A 40-year-old woman with right femoral shortening of 7 cm and distal valgus deformity:  
e, f, g, h — photograph and radiographs showed normal alignment of the lower limbs

## DISCUSSION

The aim of this reconstruction procedure was to correct the malalignment of the lower extremity and restore equal limb-length with a simplified and economical fixation. In this study, we used the Orthofix Limb Correction System equipped with MSC in all cases. MSC enables the surgeon to deal with angular deformity in planes that correspond to a safe corridor for half-pin insertion, and monorail external fixator permits gradual lengthening with one clamp locked to the rail and another clamp free to move. Our experience suggests that the application of a monorail external fixator is relatively simple and acceptable for correcting coronal plane deformities and length discrepancy through bifocal osteotomies in the femur.

The treatment of compound deformities is complicated, particularly when they are associated with limb-length discrepancies [2, 7]. Correction of all the deformities in the femur during one operation is possible with the Ilizarov circular external fixator, which allows post-operative adjustments and prevents inequality of limb lengths [8]. However, pin-track infection, bulkiness, and delayed load bearing are disadvantages that have limited the application of this methodology due to the considerable discomfort they can produce [9]. Fixator-assisted nailing and lengthening over the nail have been combined to treat femoral deformities and limb-length discrepancies [2]. Although this joint technique can decrease the duration of external fixation and promote early rehabilitation, it is technically demanding and the available space for nail accommodation after correction of severe angular deformity is limited. Moreover, only the retrograde nail can be implanted, and as it should be long enough for lengthening, partial implantation occurs before lengthening, resulting in irritation in the surrounding soft tissues. Another therapeutic possibility for the management of

distal femur deformities and concomitant shortening is using a fully implantable lengthening nail [10, 11, 12, 13, 14]. This technique eliminates the need for an external fixator to promote lengthening, which provides patients more comfort. Nevertheless, using a fully implantable lengthening nail also has limitations: an assisted external fixator is necessary to correct the distal femoral angular deformity during surgery, the articular cartilage and surrounding vascularization are damaged because of the retrograde process, and the range of correction and lengthening is limited (leading to an unavoidable secondary correction) [4]. Also, femoral distraction osteogenesis with magnetically driven antegrade intramedullary lengthening nails shows a high risk of unplanned additional surgery, and a high proportion of patients for temporary joint stiffness [15]. In particular associated with fully implantable lengthening nails, E.J. Geiger et al. reported 41% (17/41), B. Vogt et al. — 29% (13/45) and P.R. Calder et al. — 24% (8/34) of unplanned additional surgery [12, 13, 14]. In addition, weight-bearing rehabilitation is not possible during the early stage of lengthening [11]. W. El-Adly et al. reported significant correlation between the gained length and complete weight-bearing [16]. Alternatively, a monolateral fixator was previously introduced by L.T. Donnan et al. to accomplish simultaneous acute correction of distal femoral deformities and lengthening with monofocal osteotomy [17]. However, it was concluded in that study that the maximum angular correction should be less than 30°, considering that poor bone healing after distraction is associated with a decrease in lengthening [17]. Meanwhile, lengthening of the distal femur can easily cause contracture of the knee joint, thus limiting distraction length. A. Jardaly et al. reported two-level osteotomy for distal femoral deformities and lengthening of the proximal femur provides less complications including need for additional surgery [18]. However, a two-stage operation



with distraction by an Ilizarov fixator followed by an intramedullary fixation allows earlier rehabilitation exercise with not restricted mobilization [19], while this use of a combined technique does not have a significant effect on the average duration of the one-healing index [20].

All the aforementioned treatments for distal femoral malalignment deformity and limb-length discrepancy have pearls and pitfalls. In the present study, the maximum angular correction was 46°. The distal femoral transverse osteotomy was located close to the center of the rotation of angulation plane to accomplish deformity correction and fixation with the assistance of MSC. After angular rotation of the distal femur, a triangular contact surface consisting of the medial or lateral cortex and distal osteotomy end was inserted into the proximal medullary space, allowing full correction in the coronal plane and minimizing the risk of unwanted displacement in the sagittal plane. During lengthening, the secondary distal femur valgus deformity should be considered. Appropriate translation or overcorrection of distal femur should be planned individually. The lengthening osteotomy was located in the subtrochanteric area, which was beneficial for promoting new callus formation after lengthening and decreasing the impact on knee joint contracture due to the compliant soft tissue envelope of the proximal thigh. At the time of proximal half-pin insertion, the required proximal and distal retraction of the skin was achieved to avoid skin tension and facilitate femur lengthening. Moreover, the monorail external fixator used here allowed the affected lower limb to rest in its normal position and allowed checking of joint ROM and exercise weight-bearing immediately after the surgery. Thus, knee ROM at

the last follow-up visit was nearly normal in all cases. Although pin-track infection is the most frequent problem when using external fixators, compression of the adjacent tissue to each half-pin with gauze dressings appeared to be an appropriate method to keep the pin-track dry and to prevent infection. By this method, the relative motion between the soft tissue and the pin interface was reduced, especially during rehabilitation and gradual lengthening, which explains the low occurrence of pin-track infection in this study (16.7 %, corresponding to 5 patients out of 30).

The procedure studied here has some limitations. MSC is usually indicated in cases with coronal plane angular deformities, whereas multiaxial deformities generally mandate the use of a circular fixator. Furthermore, we realized that although the external fixator was simplified, patient discomfort was unavoidable. However, the method involved limited soft tissue dissection, achieved complete varus or valgus correction with MSC, and provided stability and relative convenience for lengthening with the monorail external fixator during one surgery. In addition, it is a recommendable technique in regions where motorized nailing is not available.

## CONCLUSIONS

Our results indicate that acute deformity correction and gradual lengthening using a monorail external fixator assembled with MSC through bifocal osteotomies are effective in cases of distal femoral varus/valgus deformities with concomitant shortening. Functional and cosmetic improvements are expected following the surgery and post-operative rehabilitation.

## DISCLAIMERS

### Acknowledgements

The authors would like to thank patients included in this study and all other participants from Department of Orthopedics of Shanghai Sixth People's Hospital in this work.

### Author contribution

*Kunqi Zhang* — collection and analysis of materials, text preparation and editing.

*Yifan Yu* — data statistical processing editing text.

*Feng Wang* — data statistical processing, editing text.

*Hanzhe Zhang* — collection and analysis of materials, drafting the article.

*Shanyu Li* — collection and analysis of materials, drafting the article.

*Yuting Cao* — collection and analysis of materials, editing text.

*Qinglin Kang* — research concept and design.

*Jia Xu* — collection and analysis of materials, statistical processing of data, text preparation and editing, concept and design.

## ДОПОЛНИТЕЛЬНАЯ ИНФОРМАЦИЯ

### Благодарность

Авторы выражают благодарность пациентам, включенным в исследование, и всем остальным участникам исследования из травматолого-ортопедического отделения Sixth People's Hospital в Шанхае.

### Заявленный вклад авторов

*Куньци Чжан* — сбор и анализ материала, подготовка и редактирование текста рукописи.

*Ифань Юй* — статистическая обработка данных, редактирование текста рукописи.

*Фэн Ван* — статистическая обработка данных, редактирование текста рукописи.

*Ханьчжэ Чжан* — сбор и анализ материала, написание текста рукописи.

*Шаньюй Ли* — сбор и анализ материала, написание текста рукописи.

*Юйтин Цао* — сбор и анализ материала, редактирование текста рукописи.

*Цинлинь Кан* — концепция и дизайн исследования.

*Цзя Сюй* — сбор и анализ материала, статистическая обработка данных, подготовка и редактирование текста рукописи, концепция и дизайн исследования.

All authors have read and approved the final version of the manuscript of the article. All authors agree to bear responsibility for all aspects of the study to ensure proper consideration and resolution of all possible issues related to the correctness and reliability of any part of the work.

**Funding source.** This work was supported by Shanghai Municipal Health Commission Youth Program (2022YQ005), 2021 Basic Scientific Research Cultivation Project of Shanghai Sixth People's Hospital (ynms202104) to Jia Xu, National Natural Science Foundation of China (82072421) to Qinglin Kang.

**Disclosure competing interests.** The authors declare that they have no competing interests.

**Ethics approval.** Not applicable.

**Consent for publication.** Авторы получили письменное согласие пациентов на участие в исследовании и публикацию результатов.

Все авторы прочли и одобрили финальную версию рукописи статьи. Все авторы согласны нести ответственность за все аспекты работы, чтобы обеспечить надлежащее рассмотрение и решение всех возможных вопросов, связанных с корректностью и надежностью любой части работы.

**Источник финансирования.** Данное исследование было проведено при поддержке Shanghai Municipal Health Commission Youth Program (2022YQ005), 2021 Basic Scientific Research Cultivation Project of Shanghai Sixth People's Hospital (ynms202104) для Цзя Сюй, National Natural Science Foundation of China (82072421) для Цинлинь Кан.

**Возможный конфликт интересов.** Авторы декларируют отсутствие явных и потенциальных конфликтов интересов, связанных с публикацией настоящей статьи.

**Этическая экспертиза.** Не применима.

**Информированное согласие на публикацию.** The authors obtained written consent from patients to participate in the study and publish the results.

## REFERENCES

- Gugenheim J.J.Jr., Brinker M.R. Bone realignment with use of temporary external fixation for distal femoral valgus and varus deformities. *J Bone Joint Surg Am.* 2003;85(7):1229-1237. doi: 10.2106/00004623-200307000-00008.
- Kocaoglu M., Eralp L., Bilen F.E., Balci H.I. Fixator-assisted acute femoral deformity correction and consecutive lengthening over an intramedullary nail. *J Bone Joint Surg Am.* 2009;91(1):152-159. doi: 10.2106/JBJS.H.00114.
- Black S.R., Kwon M.S., Cherkashin A.M., Samchukov M.L., Birch J.G., Jo C.H. Lengthening in Congenital Femoral Deficiency: A Comparison of Circular External Fixation and a Motorized Intramedullary Nail. *J Bone Joint Surg Am.* 2015;97(17):1432-1440. doi: 10.2106/JBJS.N.00932.
- Jardaly A., Gilbert S.R. Combined antegrade femur lengthening and distal deformity correction: a case series. *J Orthop Surg Res.* 2021;16(1):60. doi: 10.1186/s13018-020-02168-6.
- Calder P.R., McKay J.E., Timms A.J., Roskrow T., Fugazzotto S., Edel P. et al. Femoral lengthening using the Precice intramedullary limb-lengthening system: outcome comparison following antegrade and retrograde nails. *Bone Joint J.* 2019;101-B(9):1168-1176. doi: 10.1302/0301-620X.101B9.BJJ-2018-1271.R1.
- Paley D., Catagni M.A., Argnani F., Villa A., Benedetti G.B., Cattaneo R. Ilizarov treatment of tibial nonunions with bone loss. *Clin Orthop Relat Res.* 1989;(24):146-165.
- Xu J., Jia Y., Kang Q., Chai Y. Intra-articular corrective osteotomies combined with the Ilizarov technique for the treatment of deformities of the knee. *Bone Joint J.* 2017;99-B(2):204-210. doi: 10.1302/0301-620X.99B2.BJJ-2016-0736.R2.
- Xu H.F., Xu C., Sha J., Yan Y.B., Li C., Liu Z.C. et al. One-stage Surgical Treatment of Simultaneous Osteotomy and Asymmetric Lengthening on Short Femur with Severe Deformity of Genu Valgus. *Sci Rep.* 2019;9(1):8602. doi: 10.1038/s41598-019-45157-4.
- Paley D., Herzenberg J.E., Paremian G., Bhav A. Femoral lengthening over an intramedullary nail. A matched-case comparison with Ilizarov femoral lengthening. *J Bone Joint Surg Am.* 1997;79(10):1464-1480. doi: 10.2106/00004623-199710000-00003.
- Baumgart R., Burklein D., Hinterwimmer S., Thaller P., Mutschler W. The management of leg-length discrepancy in Ollier's disease with a fully implantable lengthening nail. *J Bone Joint Surg Br.* 2005;87(7):1000-1004. doi: 10.1302/0301-620X.87B7.16365.
- Iobst C.A., Rozbruch S.R., Nelson S., Fragomen A. Simultaneous Acute Femoral Deformity Correction and Gradual Limb Lengthening Using a Retrograde Femoral Nail: Technique and Clinical Results. *J Am Acad Orthop Surg.* 2018;26(7):241-250. doi: 10.5435/JAAOS-D-16-00573.
- Geiger E.J., Geffner A.D., Rozbruch S.R., Fragomen A.T. Treatment of angular deformity and limb length discrepancy with a retrograde femur magnetic intramedullary nail: a fixator-assisted, blocking screw technique. *J Am Acad Orthop Surg Glob Res Rev.* 2023;7:e23.00053. doi: e23.0005310.5435/JAAOSGlobal-D-23-00053.
- Vogt B., Biermann C., Gosheger G., Laufer A., Rachbauer A., Antfang C. et al. Simultaneous correction of leg length discrepancy and angular deformity of the distal femur with retrograde Precice nails: a retrospective analysis of 45 patients. *Acta Orthop.* 2024;95:364-372. doi: 10.2340/17453674.2024.40947.
- Calder P.R., McKay J.E., Timms A.J., Roskrow T., Fugazzotto S., Edel P. et al. Femoral lengthening using the Precice intramedullary limb-lengthening system: outcome comparison following antegrade and retrograde nails. *Bone Joint J.* 2019;101-B(9):1168-1176. doi: 10.1302/0301-620X.101B9.BJJ-2018-1271.R1.
- Frommer A., Roedel R., Gosheger G., Niemann M., Turkowski D., Toporowski G. et al. What Are the Potential Benefits and Risks of Using Magnetically Driven Antegrade Intramedullary Lengthening Nails for Femoral Lengthening to Treat Leg Length Discrepancy? *Clin Orthop Relat Res.* 2022;480(4):790-803. doi: 10.1097/CORR.0000000000002036.



16. El-Adly W., El-Gafary K., Khashaba A., Khaled M. Results of Ilizarov external fixator lengthening compared to lengthening and then plating in management of femoral shortening in children. *Acta Orthop Belg.* 2023;89(2):177-182. doi: 10.52628/89.2.9675.
17. Donnan L.T., Saleh M., Rigby A.S. Acute correction of lower limb deformity and simultaneous lengthening with a monolateral fixator. *J Bone Joint Surg Br.* 2003; 85(2):254-260. doi: 10.1302/0301-620x.85b2.12645.
18. Jardaly A., Gilbert S.R. Combined antegrade femur lengthening and distal deformity correction: a case series. *J Orthop Surg Res.* 2021;16(1):60. doi: 10.1186/s13018-020-02168-6.
19. Srikant K., Soni A., Pradhan S., Gulia A., Sandeep B., Kafley R. et al. Ilizarov Fixator-Assisted Management of Neglected Femur Fractures by Open Intramedullary Nailing: A Case Series. *Cureus.* 2023;15(12):e50864. doi: 10.7759/cureus.50864.
20. Borzunov D.Y., Kolchin S.N. Nonunion of the femoral shaft associated with limb shortening treated with a combined technique of external fixation over an intramedullary nail versus the Ilizarov method. *Arch Orthop Trauma Surg.* 2022;142(9):2185-2192. doi: 10.1007/s00402-021-03804-4.

#### Authors' information

✉ Jia Xu MD PhD

Address: 600 Yishan Road, Shanghai, China 200233

e-mail: xujia0117@126.com

<https://orcid.org/0000-0002-4899-0715>

Kunqi Zhang

<https://orcid.org/0009-0006-2070-9879>

e-mail: zhangkunqiedu@163.com

Yifan Yu MD

<https://orcid.org/0009-0008-8411-1395>

e-mail: yuyifan\_study@163.com

Feng Wang

e-mail: fwang2014@sjtu.edu.cn

Hanzhe Zhang

<https://orcid.org/0009-0007-9255-9854>

e-mail: cheunghzz@163.com

Shanyu Li MD

<https://orcid.org/0000-0001-9794-008X>

e-mail: shanyu\_li@163.com

Yuting Cao

<https://orcid.org/0009-0008-8351-6841>

e-mail: cyting@163.com

Qinglin Kang — MD PhD Professor

<https://orcid.org/0000-0001-9825-0451>

e-mail: orthokang@163.com

#### Сведения об авторах

✉ Цзя Сюй

Address: 600 Yishan Road, Shanghai, China 200233

e-mail: xujia0117@126.com

<https://orcid.org/0000-0002-4899-0715>

Куньци Чжан

<https://orcid.org/0009-0006-2070-9879>

e-mail: zhangkunqiedu@163.com

Ифань Юй

<https://orcid.org/0009-0008-8411-1395>

e-mail: yuyifan\_study@163.com

Фэн Ван

e-mail: fwang2014@sjtu.edu.cn

Ханьчжэ Чжан

<https://orcid.org/0009-0007-9255-9854>

e-mail: cheunghzz@163.com

Шаньюй Ли

<https://orcid.org/0000-0001-9794-008X>

e-mail: shanyu\_li@163.com

Юйтин Цао

<https://orcid.org/0009-0008-8351-6841>

e-mail: cyting@163.com

Цинлинь Кан — профессор

<https://orcid.org/0000-0001-9825-0451>

e-mail: orthokang@163.com