

Dead or Alive – Use of Indocyanine Green Angiography for Intraoperative Assessment of Bone Vitality in Nonunion Fractures: A Controlled Case Series of Four Patients

Emiliano Malagoli^{1,2}, Filippo Vandenbulcke², Mosheer Ziadi³, Giovanni Lucchesi⁴, Stefania Zini⁵, Alexander Kirienko^{1,2}

¹ *Humanitas Clinical and Research Center – IRCCS, Rozzano (MI), Italy*

² *Humanitas University, Department of Biomedical Sciences, Pieve Emanuele (MI), Italy*

³ *King Abdullah Medical City, Makkah, Saudi Arabia*

⁴ *Ortopediatria Center for Education, Research and Patient Care in Paediatric Orthopedics, Bologna (BO), Italy*

⁵ *Policlinico San Pietro, Ponte San Pietro (BG), Italy*

Abstract

Background. Indocyanine green (ICG) fluorescence imaging is a surgical tool with increasing applications in various surgical disciplines. During nonunion resection, the assessment of bone vascularization is currently based only on the surgeon's experience. We introduced the use of indocyanine green (ICG) angiography in orthopedics.


The aims of the study: 1) to use ICG fluorescence angiography to evaluate the bone perfusion in patients with atrophic nonunion, where poor or absent ICG flow reveals avascular tissue associated with bone necrosis requiring surgical resections; 2) to describe our case series of patients operated with this technique.


Methods. We used ICG angiography in patients operated for tibial nonunion resection. We administered 0.5 mg/kg of ICG powder dissolved in sterile saline at 2.5 mg/ml concentration. The time from the injection to the beginning of appreciation of the green dye was measured. Non-viable bone was resected accordingly. Patient underwent routine follow-up. We enrolled all the suitable patients operated from April 2019 to June 2021 and matched three control patients for each of them. We reviewed their medical records and noted any relevant data.

Results. We enrolled 4 cases and 12 controls, all male. The mean age was 30.8±6.9 years. The mean duration from trauma to surgery was 10.5 (0.7-25.0) months. The mean duration of surgery was 190.8±40.3 min. The defect size was 4.89±2.03 cm. ICG allowed rapid visualization of bone vascularization after 25-45 sec. No adverse events were observed. The mean external fixation time was 11.8±5.0 months. The mean external fixation index was 2.69±1.10. Seven patients needed a surgical revision during treatment. Three patients underwent reintervention after frame removal. There are no statistically significant differences between cases and controls.

Conclusions. The research findings of this study are limited by the small number of observations. However, this technique is safe, easy, and rapid and may contribute to intraoperative decision of how much to resect. Using ICG could objectively demonstrate bone perfusion to help surgeons to avoid massive bone defects.

Keywords: indocyanine green, fracture nonunion, bone resection, vascularization assessment.

 **Для цитирования:** Malagoli E., Vandenbulcke F., Ziadi M., Lucchesi G., Zini S., Kirienko A. Dead or Alive – Use of Indocyanine Green Angiography for Intraoperative Assessment of Bone Vitality in Nonunion Fractures: A Controlled Case Series of Four Patients. *Травматология и ортопедия России*. 2024;30(2):151-157. <https://doi.org/10.17816/2311-2905-17494>.

 *Filippo Vandenbulcke*; e-mail: filippo@vandenbulcke.org

Рукопись получена: 13.03.2024. Рукопись одобрена: 20.05.2024. Статья опубликована: 20.06.2024.

© Malagoli E., Vandenbulcke F., Ziadi M., Lucchesi G., Zini S., Kirienko A., 2024



Живая или мертвая — использование ангиографии с индоцианином зеленым для интраоперационной оценки жизнеспособности костной ткани при несращениях переломов: контролируемое исследование серии из четырех клинических случаев

Э. Малаголи^{1,2}, Ф. Ванденбулке², М. Зиади³, Д. Луккези⁴, С. Зини⁵, А. Кириенко^{1,2}

¹ *Humanitas Clinical and Research Center – IRCCS, Rozzano (MI), Italy*

² *Humanitas University, Department of Biomedical Sciences, Pieve Emanuele (MI), Italy*

³ *King Abdullah Medical City, Makkah, Saudi Arabia*

⁴ *Ortopediatria Center for Education, Research and Patient Care in Paediatric Orthopedics, Bologna (BO), Italy*

⁵ *Policlinico San Pietro, Ponte San Pietro (BG), Italy*

Реферат

Введение. Флуоресцентная визуализация индоцианином зеленым (ICG) — это хирургический метод исследования, который находит все более широкое применение в различных хирургических специальностях. В настоящее время оценка жизнеспособности костной ткани в ходе резекции по поводу несращения перелома основывается только на опыте хирурга. Мы апробировали ангиографию с индоцианином зеленым при ортопедических вмешательствах.

Материал и методы. ICG-ангиография проводилась пациентам, которым выполняли резекцию большеберцовой кости по поводу несращения. Мы вводили 0,5 мг/кг порошка с ICG, растворенного в стерильном физрастворе в концентрации 2,5 мг/мл. Измеряли время от инъекции до обнаружения зеленого красителя в зоне несращения. На основании полученного результата нежизнеспособная костная ткань резецировалась. Пациент проходил плановое наблюдение. В исследование вошли все пациенты, удовлетворяющие критериям включения и прооперированные с апреля 2019 по июнь 2021 г. Для каждого пациента были подобраны по три контрольных пациента. Мы изучили их медицинские документы и зафиксировали все клинически значимые данные.

Результаты. В исследование были включены 4 исследуемых пациента и 12 контрольных, все мужчины. Средний возраст составил 30,8±6,9 года, среднее время от травмы до операции — 10,5 (0,7–25,0) мес., средняя длительность операции — 190,8±40,3 мин. Средний размер дефекта был равен 4,89±2,03 см. ICG-ангиография позволяла оценить степень васкуляризации костной ткани через 25–45 сек. с момента введения красителя. Нежелательных явлений не наблюдалось. Средняя продолжительность внешней фиксации составила 11,8±5,0 мес., средний индекс внешней фиксации — 2,69±1,10. В ходе лечения семи пациентам потребовалась хирургическая ревизия. Трем пациентам было проведено повторное вмешательство после демонтажа аппарата. Статистически значимых различий между группой исследования и контрольной группой выявлено не было.

Заключение. Результаты данного исследования ограничены небольшим количеством наблюдений. Тем не менее описанный метод исследования безопасен и прост, при необходимости позволяет во время операции быстро принять решение об объеме резекции. ICG-ангиография является объективным методом визуализации перфузии кости, помогая хирургам избежать массивных костных дефектов.

Ключевые слова: индоцианин зеленый, несращение перелома, резекция костной ткани, оценка васкуляризации.

Cite as: Малаголи Э., Ванденбулке Ф., Зиади М., Луккези Д., Зини С., Кириенко А. Живая или мертвая — использование ангиографии с индоцианином зеленым для интраоперационной оценки жизнеспособности костной ткани при несращениях переломов: контролируемое исследование серии из четырех клинических случаев. *Traumatology and Orthopedics of Russia*. 2024;30(2):151-157. <https://doi.org/10.17816/2311-2905-17494>.

✉ Филиппо Ванденбулке; e-mail: filippo@vandenbulcke.org

Submitted: 13.03.2024. Accepted: 20.05.2024. Published: 20.06.2024.

© Малаголи Э., Ванденбулке Ф., Зиади М., Луккези Д., Зини С., Кириенко А., 2024

INTRODUCTION

Neoplastic pathology, congenital deformity, and post-traumatic conditions could result in large bone defects. The management of such bone defects, including maintaining bone length and achieving bone union, remains a challenge to orthopedic surgeons [1, 2, 3]. Many reconstructive techniques are available to reach these objectives. All these procedures include meticulous debridement of all necrotic tissues and stabilization of the skeleton [4, 5]. Assessment of arterial perfusion and venous drainage are important prognostic criteria [6, 7].

Nonetheless, intraoperative assessment is based predominantly on the subjective characteristics, such as tissue color, capillary reperfusion, and the presence of “paprika sign”, a punctuate bleeding from osseous vessels [8, 9, 10, 11]. Therefore, the success of bone defect treatment is strongly dependent on the experience of the operating surgeon. None of these measures have been applied systematically because they are not reliable and repeatable [11].

Fluorescent imaging with indocyanine green (ICG) is a useful technology currently used in several surgical fields, such as reconstructive flap in plastic surgery, colorectal resection and anastomosis, to determine tissue perfusion [12, 13, 14, 15, 16, 17]. ICG binds to plasma lipoproteins and emits a fluorescent signal when excited by near-infrared light, providing anatomic information about organ vascularization and tissue perfusion [12, 13, 18]. The benefits of fluorescent imaging with ICG include high contrast (all tissues are enhanced except for necrotic one), high sensitivity (extremely small concentrations can often be made visible), low cost and ease of use. Furthermore, ICG fluorescence is safe because it is nontoxic and nonionizing, and adverse reactions related to its clinical use are rare; it has a short lifetime in blood circulation allowing repeated applications [5, 13, 19]. During our literature search, we found no documentation of the ICG use in orthopedic trauma [20].

The aims of the study: 1) to use ICG fluorescence angiography to evaluate the bone perfusion in patients with atrophic nonunion, where poor or absent ICG flow reveals avascular tissue associated with bone necrosis requiring surgical resections; 2) to describe our case series of patients operated with this technique.

METHODS

Preoperative assessment

Our preoperative assessment protocol includes:

- interview for a history of iodine allergy or previous anaphylactic reaction to contrast media or dye injection;
- limb examination for neurovascular status and skin condition;

- evaluation of clinical and biochemical evidence of active infection (draining sinus, local inflammation, pain, tenderness, swelling);

- X-ray and CT scan for radiographic assessment of the level and size of bone defect, bone quality, and signs of infection (cavities, sequestered and sclerotic bone);

- PET/CT or MRI as a second-level investigation to better establish the limits of bone necrosis.

Patients

Due to the explorative nature of this study, it enrolled all the suitable patients from April 2019 to June 2021 and matched three control patients for each of them coupled for age (± 5 years), sex, and bone defect size (± 3.5 cm). We estimated four patients in the ICG group, a control cohort composed by 12 patients, so the final sample size accounted for 16 patients.

Angiography technique

Among several fluorescent angiography systems available we use Stryker Platform (ENV, Stryker Endoscopy, USA), which has already been available in our institute. The fluorescent dye ICG is intravenously administered, and the tissue in the region of interest is illuminated using near-infrared light at a wavelength of 830 nm; the total output is 80 mW in a field of view of 10 cm in diameter, operating at a distance of approximately 30 cm above the tissue [18]. ICG in powder form (25 mg/vial) is water-soluble and albumin-bound. Its plasma half-life is 3-5 min., and its biliary excretion is completed in 15-20 min. [14]. The blood and ICG suspension under a tissue absorbs the excitation wavelengths and emits a fluorescent band. The emitted light is detected by an infrared-sensitive charge-coupled device camera system through a low-pass filter.

Operative technique

After anesthesia, the patient is placed on the operating table in the supine position. A tourniquet is applied on the upper thigh. The skin incision is made on the nonunion site. Implants are removed where present and tissue samples are obtained for microbiological analysis. The circular external fixator (the Ilizarov frame manufactured by Sintea Plustek s.r.l.) is placed. After the preliminary soft tissue debridement is completed, the tourniquet is deflated. The ICG angiography device is draped and brought into the field. The ICG powder is dissolved in sterile saline at 2.5 mg/ml concentration. The ICG dye solution is injected intravenously as a bolus at a dose of 0.2-0.5 mg/kg body weight (e.g., 8 ml of ICG for a patient weighing 80 kg). The time from the injection and the beginning of an appreciation of the green area is measured. The area of the tissue examined is centered within the screen, including also a tissue with normal perfusion using it as an internal reference.

Observation is made at a distance of 30-50 cm from the tissue of interest. ICG becomes fluorescent once excited by near-infrared light at wavelengths of 830 nm. The fluorescence intensity reaches its maximum within the first 60 sec after injection, and then slowly decreases, depending on the perfusion conditions and hepatic elimination. After resection of necrotic bone, angiography might be repeated waiting approximately 3-5 min. after the initial run to obtain a wash out of the dye from the tissues. If the dye still shows evidence of an avascular bone, further resection is necessary.

After resection, we use bone transport to treat defects >3-5 cm. The osteotomy is performed and the segment is transported gradually (0.25 mm four times per day) to the other side of the defect to regenerate the bone by distraction osteogenesis. In these patients, partial weight-bearing is allowed. To treat bone defects <3-5 cm, we use acute compression at the nonunion level and osteotomy for progressive lengthening (Fig. 1). In these cases, patients are allowed to fully weight-bear immediately. After the procedure is completed, the subcutaneous tissue and skin are sutured, and 2 g of prophylactic cefazolin is administered.

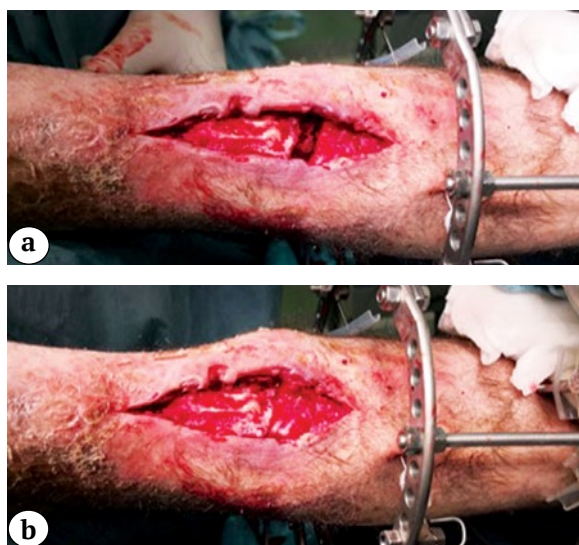


Fig. 1. Nonunion before (a) and after (b) acute compression during surgery

Statistical analysis

Data were described as frequencies and percentages for qualitative variables, or as median, minimum and maximum value (range). Differences between groups were explored using the chi-square test and Fisher correction, for categorical variables, or with the Mann-Whitney U test for continuous variables. P-values lower than 0.05 were considered as statistically significant. All analyses were made with Stata

(StataCorp. 2023. Stata Statistical Software: Release 18. College Station, TX: StataCorp LLC).

RESULTS

Cohort description

We enrolled 16 patients undergone bone resection for septic nonunion of the tibia and reconstruction with the Ilizarov method: 4 cases and 12 controls. All surgical procedures were performed by the same surgeon. The mean age was 30.8±6.9 years. All patients were male. The mean duration from trauma to surgery was 10.5 (0.7-25) months. The mean duration of surgery was 190.8±40.3 min. The defect size was 4.89±2.03 cm. The affected bone segment was the proximal tibia in 2 patients (12.50%), the tibial shaft in 9 patients (56.25%) and the distal tibia in 5 patients (31.25%). There are no statistically significant differences between cases and controls (Table 1).

Surgical procedure

During the surgery, ICG analysis guided the identification of bone perfusion and supplied information about the surrounding vascular anatomy. In 25-45 sec after the dye solution was injected, the visual effects were observed on the surface of the resecting bone (Fig. 2). ICG fluorescence imaging under near-infrared light was obvious and distinguishable in all patients. In addition, during bone resection, the visual effect of ICG fluorescence continued. We confirmed the bone boundary by observing ICG fluorescence on the cut surface of the resecting side. As indicated in Supplemental Video 1, the appearance of the bone changed from a faint or absent area on the necrotic bone to a clear bright area after debridement and osteotomy. During all procedures, we compared the area of interest with tissues with normal perfusion for use as an internal reference. The ICG angiography was repeated after 10±15 min. to confirm complete resection of necrotic bone (Fig. 3). A minimal residual fluorescence was visible before the new ICG injection that did not negatively affect the image quality of the new ICG angiography.

Outcomes and complications

The average external fixation time was 11.8±5.0 months. The average external fixation index was 2.69±1.10. After ICG was injected, the oxygen level was reduced due to a bias in the pulse oximeter reading without any clinical relevance. However, no other local or systemic complications were noted during or after surgery. Seven patients needed a surgical revision surgery during external fixation time. Three patients underwent a reintervention after frame removal. There are no statistically significant differences between cases and controls (Table 1).

Table 1

Characteristics, outcome and complications of patients undergone bone resection for septic nonunion of the tibia and reconstruction with the Ilizarov method

Parameter	All	Cases	Controls	p
Number of patients	16	4	12	
Age, years	30.8±6.9	30.3±6.8	31.0±7.2	0.789
Duration from trauma to surgery, mons	10.5 (0.7-25)	18.5 (10-25)	8.5 (0.7-20)	0.070
Defect size, cm	4.89±2.02	4.50±2.35	5.03±2.00	0.720
District				0.769
Proximal tibia	2 (12.50%)	0	2 (16.67%)	
Tibial shaft	9 (56.25%)	2 (50.00%)	7 (58.33%)	
Distal tibia	5 (31.25%)	2 (50.00%)	3 (25.00%)	
Surgery duration, min	190.8±40.3	185.8±34.5	192.4±43.4	0.770
TEF	11.8±5.0	14.0±6.5	11.0±4.5	0.578
EFI	2.69±1.10	3.25±0.56	2.51±1.19	0.204
Revision	7 (43.75%)	2 (50.00%)	5 (41.67%)	1.000
Re-surgery	3 (18.75%)	2 (50.00%)	1 (8.33%)	0.136
Re-surgery, n		1	3	
Revision or re-surgery, n	1 (0-3)	1 (0-2)	0.5 (0-3)	0.515

*p<0.05.

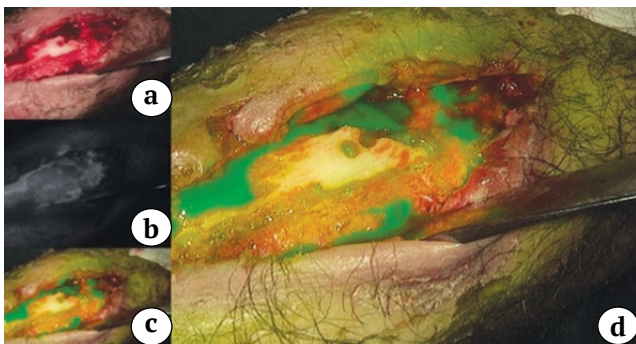


Fig. 2. Nonunion site before bone resection. Pictures show the normal view (a), lights off (b), and monitor view with lights off and the infrared lamp on (c, d)

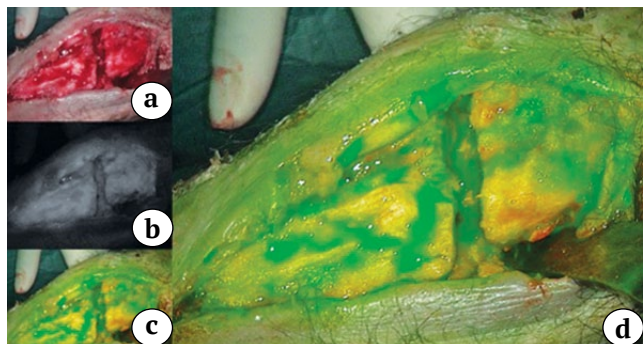


Fig. 3. Nonunion site after bone resection. Pictures show the normal view (a), lights off (b), and monitor view with lights off with the infrared lamp on (c, d)

DISCUSSION

In the treatment of nonunion fractures, surgeons often deal with necrotic tissues resection. Despite technical advances, the surgeons continue to assess bone viability without any instrument. Therefore, the success of the surgical procedures depends on the surgeon's experience. However, large bone defects may sometimes occur because of the surgeon's decision to resect the affected bone in a completely subjective manner. In our study, we explored the potential of indocyanine green (ICG) fluorescence angiography as a novel technique for assessing bone perfusion in patients with atrophic nonunion. Our findings show the feasibility and utility of ICG fluorescence imaging in guiding surgical decision-making. ICG fluorescence imaging helps the surgeon to establish limits of resection basing on objective parameters in addition to preoperative planning on PET/CT or MRI. Thus, one can avoid over- or underestimation of tissue to resect.

The same technique is routinely applied in different fields such as colorectal [14], plastic and

gynecological surgery [15, 16, 17]. A recent review by S.S. Streeter et al. comprehensively reports current and future applications of fluorescence guidance in orthopedics [21]. Regarding traumatology, an ICG-based dynamic contrast-enhanced fluorescence imaging (DCE-FI) was developed to objectively assess and quantify endosteal and periosteal perfusion in a porcine trauma model [22, 23].

Our results were confirmed by a clinical study on 42 patients with high-energy open fractures. Moreover, ICG-based DCE-FI compared to intraoperative DCE-magnetic resonance imaging (MRI), demonstrated higher sensitivity to perfusion changes, while DCE-MRI provided superior depth-related perfusion information [24]. Furthermore, an automated motion artifact correction approach was developed to reduce motion artifacts due to the patient's involuntary respiration during data acquisition and to improve the accuracy of bone perfusion assessment [25].

The use of ICG angiography was described also for perfusion assessment of scaphoid nonunions and it

showed promising results to improve intraoperative decision-making [26]. ICG fluorescence imaging offers several advantages over conventional subjective intraoperative assessment methods. Firstly, it provides real-time visualization of tissue perfusion, allowing surgeons to accurately identify areas of compromised vascularity and necrotic bone. This capability is particularly crucial in cases of atrophic nonunion, where impaired blood supply can impede successful bone healing. By precisely delineating viable tissue, ICG angiography helps to guide the extent of debridement, ensuring thorough removal of necrotic material while preserving a healthy bone.

Secondly, ICG fluorescence imaging enhances intraoperative decision-making by providing objective, quantifiable data on tissue perfusion. Unlike subjective assessments based on visual cues such as tissue color and capillary refill, ICG angiography offers a standardized method for evaluating vascular integrity.

Furthermore, the safety profile of ICG makes it a viable option for routine use in orthopedic trauma surgery. Its low toxicity and minimal risk of adverse reactions ensure patient safety, while its short half-life and rapid excretion minimize the duration of exposure. This makes ICG angiography a practical and cost-effective intraoperative imaging modality, with the potential to improve outcomes and reduce healthcare costs associated with nonunion management.

DISCLAIMERS

Acknowledgements. We extend our gratitude to Emanuela Morengi, MA for her support in study design and statistical analysis.

Funding source. This study was not supported by any external sources of funding.

Disclosure competing interests. The authors declare that they have no competing interests.

Ethics approval. The study was approved by the Comitato Etico Territoriale Lombardia 5 (protocol N 1, 22.02.2024).

Consent for publication. The authors obtained written consent from patients to participate in the study and publish the results.

REFERENCES

- Mumford J.E., Simpson A.H.R.W. Management of Bone Defects. A Review of Available Techniques. *Iowa Orthop J.* 1992;12:42-49.
- Nauth A., McKee M.D., Einhorn T.A., Watson J.T., Li R., Schemitsch E.H. Managing Bone Defects. *J Orthop Trauma.* 2011;25(8):462-466. doi: 10.1097/BOT.0b013e318224caf0.
- Mauffrey C., Barlow B.T., Smith W. Management of Segmental Bone Defects. *J Am Acad Orthop Surg.* 2015;23(3):143-153. doi: 10.5435/JAAOS-D-14-00018.
- El-Rosasy M., Mahmoud A., El-Gebaly O., Lashin A., Rodriguez-Collazo E. Debridement technique and dead space management for infected non-union of the tibia. *Int J Orthoplast Surg.* 2019;2(1):29-36. doi: 10.29337/IJOPS.34.

Our paper opens new perspectives that can help surgeons in performing bone resections to preserve vital tissues where antibiotic and immune cells might be delivered. The use of ICG fluorescence imaging in surgery continues to evolve. Concerning nonunions treatment, it can assist surgeons in intraoperative decision-making to establish the resection levels avoiding massive bone defects.

While our study demonstrates promising results, several limitations warrant consideration. The sample size was small limiting the generalizability of our findings. Larger multicenter studies are needed to further validate the efficacy of ICG fluorescence imaging in nonunion management and to explore its applicability across different patient populations and clinical scenarios.

Conclusions

Our study highlights the potential of ICG fluorescence angiography as a valuable tool in the management of atrophic nonunion. By providing real-time assessment of tissue perfusion and guiding surgical decision-making, ICG imaging enhances the precision and effectiveness of reconstructive procedures, ultimately improving outcomes for patients with complex bone defects. Further research is warranted to validate these findings and optimize the integration of ICG angiography into routine orthopedic practice.

ДОПОЛНИТЕЛЬНАЯ ИНФОРМАЦИЯ

Благодарность. Мы выражаем благодарность Э. Моренги за помощь в разработке дизайна исследования и выполнении статистического анализа.

Источники финансирования. Авторы заявляют об отсутствии внешнего финансирования при проведении исследования.

Возможный конфликт интересов. Авторы декларируют отсутствие явных и потенциальных конфликтов интересов, связанных с публикацией настоящей статьи.

Этическая экспертиза. Исследование одобрено локальным этическим комитетом Ломбардии 5 (выписка из протокола № 1 от 22.02.2024).

Информированное согласие на публикацию. Авторы получили письменное согласие пациентов на участие в исследовании и публикацию результатов.

- Chaudhary M.M. Infected nonunion of tibia. *Indian J Orthop.* 2017;51(3):256-268. doi: 10.4103/ortho.IJOrtho.199.16.
- Ghareeb P.A., Neustein T.M., Fang R.C., Payne D.E. Indocyanine Green Angiography: A Helpful Tool for Intraoperative Assessment of Upper Extremity Perfusion. *Tech Hand Up Extrem Surg.* 2017;21(3):101-106. doi: 10.1097/BTH.000000000000162.
- Mothes H., Dönicke T., Friedel R., Simon M., Markgraf E., Bach O. Indocyanine-Green Fluorescence Video Angiography Used Clinically to Evaluate Tissue Perfusion in Microsurgery. *J Trauma.* 2004;57(5):1018-1024. doi: 10.1097/01.TA.0000123041.47008.70.
- Hannan C.M., Attinger C.E. Special Considerations in the Management of Osteomyelitis Defects (Diabetes, the

- Ischemic or Dysvascular Bed, and Irradiation). *Semin Plast Surg.* 2009;23(2):132-140. doi: 10.1055/s-0029-1214165.
9. Parsons B., Strauss E. Surgical management of chronic osteomyelitis. *Am J Surg.* 2004;188(1A Suppl): 57S-66S. doi: 10.1016/S0002-9610(03)00292-7.
 10. Cierny G. 3rd, Mader J.T., Penninck J.J. A Clinical Staging System for Adult Osteomyelitis. *Clin Orthop Relat Res.* 2003;414:7-24. doi: 10.1097/01.blo.0000088564.81746.62.
 11. Tetsworth K., Cierny G. 3rd. Osteomyelitis Debridement Techniques. *Clin Orthop Relat Res.* 1999;(360):87-96. doi: 10.1097/00003086-199903000-00011.
 12. Doi N., Izaki T., Miyake S., Shibata T., Ishimatsu T., Shibata Y. et al. Intraoperative evaluation of blood flow for soft tissues in orthopaedic surgery using indocyanine green fluorescence angiography: A pilot study. *Bone Joint Res.* 2019;8(3):118-125. doi: 10.1302/2046-3758.83.BJR-2018-0151.R1.
 13. Alander J.T., Kaartinen I., Laakso A., Pättilä T., Spillmann T., Tuchin V.V. et al. A Review of Indocyanine Green Fluorescent Imaging in Surgery. *Int J Biomed Imaging.* 2012;2012: 940585. doi: 10.1155/2012/940585.
 14. Keller D.S., Ishizawa T., Cohen R., Chand M. Indocyanine green fluorescence imaging in colorectal surgery: overview, applications, and future directions. *Lancet Gastroenterol Hepatol.* 2017;2(10):757-766. doi: 10.1016/S2468-1253(17)30216-9.
 15. Capozzi V.A., Monfardini L., Sozzi G., Armano G., Rosati A., Gueli Alletti S. et al. Subcutaneous Vulvar Flap Viability Evaluation With Near-Infrared Probe and Indocyanine Green for Vulvar Cancer Reconstructive Surgery : A Feasible Technique. *Front Surg.* 2021;8:1-5. doi: 10.3389/fsurg.2021.721770.
 16. Capozzi V.A., Ceni V., Sozzi G., Cianciolo A., Gambino G., Pugliese M. et al. Endoscopic near infrared and indocyanine green to verify the viability of the subcutaneous flap for vulvar cancer. *Gynecol Oncol.* 2019;154(3):653-654. doi: 10.1016/j.ygyno.2019.06.018.
 17. Holm C., Tegeler J., Mayr M., Becker A., Pfeiffer U.J., Muhlbauer W. Monitoring free flaps using laser-induced fluorescence of indocyanine green: a preliminary experience. *Microsurgery.* 2002;22:278-287. doi: 10.1002/micr.10052.
 18. Duprée A., Rieß H., Detter C., Debus E.S., Wipper S.H. Utilization of indocyanine green fluorescent imaging (ICG-FI) for the assessment of microperfusion in vascular medicine. *Innov Surg Sci.* 2018;3(3):193-201. doi: 10.1515/iss-2018-0014.
 19. Miwa M., Shikayama T. ICG fluorescence imaging and its medical applications. In: 2008 International Conference on Optical Instruments and Technology: Optoelectronic Measurement Technology and Applications. 2009;7160:1-9. doi: 10.1117/12.817856.
 20. Kim S.H., Cho W.S., Joung H.Y., Choi Y.E., Jung M. Perfusion of the Rotator Cuff Tendon According to the Repair Configuration Using an Indocyanine Green Fluorescence Arthroscope. A Preliminary Report. *Am J Sports Med.* 2016;45(3):659-665. doi: 10.1177/0363546516669778.
 21. Streeter S.S., Hebert K.A., Bateman L.M., Ray G.S., Dean R.E., Geffken K.T. et al. Current and Future Applications of Fluorescence Guidance in Orthopaedic Surgery. *Mol Imaging Biol.* 2023;25(1):46-57. doi: 10.1007/s11307-022-01789-z.
 22. Jiang S., Elliott J.T., Gunn J.R., Xu C., Ruiz A.J., Henderson E.R. et al. Endosteal and periosteal blood flow quantified with dynamic contrast-enhanced fluorescence to guide open orthopaedic surgery. *Proc SPIE Int Soc Opt Eng.* 2020;11222:112220F. doi: 10.1117/12.2546173.
 23. Gitajn I.L., Elliott J.T., Gunn J.R., Ruiz A.J., Henderson E.R., Pogue B.W. et al. Evaluation of bone perfusion during open orthopedic surgery using quantitative dynamic contrast-enhanced fluorescence imaging. *Biomed Opt Express.* 2020;11(11):6458-6469. doi: 10.1364/BOE.399587.
 24. Tang Y., Sin J.M., Gitajn I.L., Cao X., Han X., Elliott J.T., et al. Dynamic contrast-enhanced fluorescence imaging compared with MR imaging in evaluating bone perfusion during open orthopedic surgery. *Proc SPIE Int Soc Opt Eng.* 2022;11943:119430C. doi: 10.1117/12.2608382.
 25. Tang Y., Gitajn I.L., Cao X., Han X., Elliott J.T., Yu X. et al. Automated motion artifact correction for dynamic contrast-enhanced fluorescence imaging during open orthopedic surgery. *Proc SPIE Int Soc Opt Eng.* 2023;12361:1236104. doi: 10.1117/12.2650028.
 26. Mulica M., Horch R., Arkudas A., Cai A., Müller-Seubert W., Hauck T. et al. Does indocyanine green fluorescence angiography impact the intraoperative choice of procedure in free vascularized medial femoral condyle grafting for scaphoid nonunions? *Front Surg.* 2022;9:962450. doi: 10.3389/fsurg.2022.962450.

Authors' information

✉ *Emiliano Malagoli*

Address: Via Rita Levi Montalcini 4, 20090, Pieve Emanuele (MI), Italy

<http://orcid.org/0000-0003-0239-080X>

e-mail: emiliano.malagoli@gmail.com

Filippo Vandenbulcke

<http://orcid.org/0000-0002-4603-659X>

e-mail: filippo.vandenbulcke@humanitas.it

Mosheer Ziadi

<http://orcid.org/0000-0002-9720-862X>

e-mail: science66@gmail.com

Giovanni Lucchesi

<http://orcid.org/0000-0002-5262-8073>

e-mail: lucchesigiovanni@gmail.com

Stefania Zini

e-mail: stefaniazini@hotmail.it

Alexander Kirienko

<http://orcid.org/0000-0003-0107-3423>

e-mail: alexander@kirienko.com

Сведения об авторах

✉ *Эмилиано Малаголи*

Адрес: Via Rita Levi Montalcini 4, 20090, Pieve Emanuele (MI), Italy

<http://orcid.org/0000-0003-0239-080X>

e-mail: emiliano.malagoli@gmail.com

Филиппо Ванденбулке

<http://orcid.org/0000-0002-4603-659X>

e-mail: filippo.vandenbulcke@humanitas.it

Мошир Зиади

<http://orcid.org/0000-0002-9720-862X>

e-mail: science66@gmail.com

Джованни Луккези

<http://orcid.org/0000-0002-5262-8073>

e-mail: lucchesigiovanni@gmail.com

Стефания Зини

e-mail: stefaniazini@hotmail.it

Александр Кириенко

<http://orcid.org/0000-0003-0107-3423>

e-mail: alexander@kirienko.com