



Surgical Approaches for Acetabulum Fracture Treatment: Analytic Review

Alexander I. Kolesnik¹, Sergey V. Donchenko², Vladislav V. Surikov^{2,3}, Dmitry A. Ivanov⁴, Evgeniy P. Tarasov⁵, Dmitry M. Yarmamedov⁶, Ivan M. Solodilov⁷

¹ Cytoproject LLC, Moscow, Russia

² Botkin City Clinical Hospital, Moscow, Russia.

³ Russian Medical Academy of Continuing Postgraduate Education, Moscow, Russia

⁴ Lytkarino City Hospital, Lytkarino, Russia

⁵ Odintsovo City Hospital, Odintsovo, Russia

⁶ Kursk State Medical University, Kursk, Russia

⁷ Kursk City Clinical Hospital No. 4, Kursk, Russia

Background. The use of classical and modified surgical approaches to acetabulum is accompanied by serious intra- and postoperative complications associated with tissues, vessels, nerves, and lymphatic structures injury. The choice of approach to acetabulum affects the surgical time and the blood loss volume.

The aim of the review was to compare the surgical time and blood loss volume using different surgical approaches to the acetabulum based on the relevant literature analysis.

Methods. The search was carried out in PubMed/MEDLINE and Scopus databases from 1964 to 2022. When conducting a search for the phrases acetabular fractures, surgical approach to the acetabulum, 4368 articles were found. As a result of the selection, 12 publications containing the most complete information on the studied indicators were included in the quantitative analysis.

Results. The data of surgical treatment of 540 patients with acetabulum fractures were analyzed. The average age of the patients was 45.2±11.6 years. Among the causes of pelvic and acetabulum fractures, road accident (70.4%) and falls from height (21.3%) largely prevailed. The blood loss depended on the use of specific approaches or their combination, and the surgical time. The shortest surgical time (101.0±27.0 min.) was required using pararectal approach, the longest (264±56.4 min.) – with the use of ilio-inguinal approach. The largest volume of blood loss was observed with Pfannenstiel approach – 1057.1±377.9 ml. No statistically significant differences were found when comparing the Kocher-Langenbeck (793±328 ml), ilio-inguinal (828±64 ml) and pararectal (798±322 ml) approach. Performing the Kocher-Langenbeck approach in the patient's lateral position reduces the surgical time by 16.8% and reduces blood loss by 12.4% compared to the patient's prone position.

Conclusion. Comparative clinical studies are required to determine the safest surgical approaches to the acetabulum, depending on the type of fracture, the mechanism of injury and the age of the patient.

Keywords: surgical approaches to the acetabulum, acetabulum fractures, surgical time, blood loss volume.

Cite as: Kolesnik A.I., Donchenko S.V., Surikov V.V., Ivanov D.A., Tarasov E.P., Yarmamedov D.M., Solodilov I.M. [Surgical Approaches for Acetabulum Fracture Treatment: Analytic Review]. *Travmatologiya i ortopediya Rossii* [Traumatology and Orthopedics of Russia]. 2022;28(3):106-115. (In Russian). <https://doi.org/10.17816/2311-2905-1747>.

✉ Alexander I. Kolesnik; e-mail: ko-lesnik@mail.ru

Submitted: 27.02.2022. Accepted: 05.07.2022. Published: 12.09.2022.

© Kolesnik A.I., Donchenko S.V., Surikov V.V., Ivanov D.A., Tarasov E.P., Yarmamedov D.M., Solodilov I.M., 2022



Обзорная статья
УДК 616.718.16-001.5-089
<https://doi.org/10.17816/2311-2905-1747>

Хирургические доступы при лечении переломов вертлужной впадины: аналитический обзор литературы

А.И. Колесник¹, С.В. Донченко², В.В. Суриков^{2,3}, Д.А. Иванов⁴, Е.П. Тарасов⁵,
Д.М. Ярмамедов⁶, И.М. Солодилов⁷

¹ ООО «ЦИТОпроект», г. Москва, Россия

² ГБУЗ «Городская клиническая больница им. С.П. Боткина» Департамента здравоохранения г. Москвы, г. Москва, Россия

³ ФГБОУ ДПО «Российская медицинская академия непрерывного профессионального образования» Минздрава России, г. Москва, Россия

⁴ ГБУЗ МО «Лыткаринская городская больница», г. Лыткарино, Россия

⁵ ГБУЗ МО «Одинцовская областная больница», г. Одинцово, Россия

⁶ ФГБОУ ВО «Курский государственный медицинский университет» Минздрава России, г. Курск, Россия

⁷ ОБУЗ «Курская городская клиническая больница № 4», г. Курск, Россия

Актуальность. Применение классических и модифицированных хирургических доступов к вертлужной впадине (ВВ) сопровождается серьезными интра- и послеоперационными осложнениями, связанными с травматизацией тканей, сосудов, нервов, лимфатических структур. Выбор доступа к ВВ влияет на длительность оперативного вмешательства и объем кровопотери.

Цель обзора — на основе анализа литературы сравнить длительность оперативного вмешательства и объем кровопотери при использовании разных хирургических доступов к вертлужной впадине.

Материал и методы. Поиск проводили в базах данных PubMed (MEDLINE) и Scopus с 1964 по 2022 г. При проведении поиска по словосочетаниям acetabular fractures, surgical approach to the acetabulum было найдено 4368 статьи. В результате отбора было включено в анализ 12 публикаций, содержащих наиболее полную информацию по изучаемым показателям.

Результаты. Проанализированы данные оперативного лечения 540 пациентов с переломами ВВ. Средний возраст пациентов составил 45,2±11,6 лет. Среди причин травм таза и ВВ в значительной степени преобладали автодорожная травма (70,4%) и кататравма (21,3%). Объем кровопотери зависел от применения конкретных доступов или их комбинации и продолжительности оперативного вмешательства. Наименьшее количество времени (101,0±27,0 мин.) потребовалось для выполнения операций с использованием параректального доступа, наибольшее (264±56,4 мин.) — с применением подвздошно-пахового доступа. Наибольший объем кровопотери отмечен при доступе Пфанненштиля — 1057,1±377,9 мл. При сравнении доступов Кохера–Лангенбека (793±328 мл), подвздошно-пахового (828±64 мл) и параректального (798±322 мл) доступов не выявлено статистически значимых отличий. Выполнение доступа Кохера–Лангенбека в положении пациента лежа на боку позволяет сократить время операции на 16,8% и сократить объем кровопотери на 12,4% в сравнении с положением пациента лежа на животе.

Заключение. Требуется проведение сравнительных клинических исследований для определения наиболее безопасных хирургических доступов к вертлужной впадине в зависимости от типа перелома, механизма травмы и возраста пациента.

Ключевые слова: хирургические доступы к вертлужной впадине, переломы вертлужной впадины, длительность операции, объем кровопотери.

Колесник А.И., Донченко С.В., Суриков В.В., Иванов Д.А., Тарасов Е.П., Ярмамедов Д.М., Солодилов И.М. Хирургические доступы при лечении переломов вертлужной впадины: аналитический обзор литературы. *Травматология и ортопедия России*. 2022;28(3):106–115. <https://doi.org/10.17816/2311-2905-1747>.

Колесник Александр Иванович; e-mail: ko-lesnik@mail.ru

Рукопись получена: 27.02.2022. Рукопись одобрена: 05.07.2022. Статья опубликована: 12.09.2022.

© Колесник А.И., Донченко С.В., Суриков В.В., Иванов Д.А., Тарасов Е.П., Ярмамедов Д.М., Солодилов И.М., 2022

BACKGROUND

The problem of surgical treatment of acetabular fractures remains relevant [1, 2, 3, 4, 5, 6]. The incidence of acetabular fractures ranges from 2% to 22% with an upward trend [1, 3, 7]. Classical and modified surgical approaches to the acetabulum are accompanied by serious intra- and post-operative complications in 8-59% of cases [3]. Complications are associated primarily with the traumatization of tissues, vessels, nerves, and lymphatic structures, operative time up to ≥ 3 h, and significant blood loss [1, 7, 8, 9, 10, 11], which become serious deterrents to the widespread use of approaches in the acute period of injury [12, 13, 14, 15, 16].

The review aimed to compare the operative time and blood loss volume when using different surgical approaches to the acetabulum based on the literature analysis.

METHODS

The search was performed in PubMed (MEDLINE) and Scopus for the period from 1964 to 2022.

The selection criteria: full-text versions of articles and abstracts containing complete information on the most commonly used standard and modified surgical approaches to the acetabulum, age of the patients, mechanism of injury, operative time, blood loss volume, and patient's position on the operating table. The language of publications was English.

The exclusion criteria: experimental studies, clinical cases, and literature reviews.

When searching for the keywords "acetabular fractures" and "surgical approach to the acetabulum," 4368 articles were found, of which 12 publications that contained the most complete information on the studied parameters were selected [1, 11, 17, 18, 19, 20, 21, 22, 23, 24, 25, 26].

Statistical analysis

Data comparison was performed using SPSS Statistics for Windows, version 11.0 (SPSS Inc., Chicago, USA). Parametric and nonparametric data were compared using unpaired Student's t-test, Mann-Whitney U-test, and χ^2 test. Differences were considered significant at $p < 0.05$.

RESULTS

We analyzed the results of the surgical treatment of 540 patients with acetabular fractures, whose data are presented in the 12 publications selected for analysis (Table 1).

Age of patients

The mean age of the patients in all studies was 45.2 ± 11.6 years. The youngest patients were registered in the studies by Khira et al. (32.9 [21.0-58.0] years) [17], Li et al. (32.1 ± 14.6 years) [18], and Salameh et al. (34.8 [18.0-60.0] years) [21]. Older patients were enrolled in the studies by Lont et al. (70 [56-92] years) [19] and T. Borg et al. (76.5 [64.0-89.0] years using the use of the Kocher-Langenbeck approach and 68.2 [50.0-83.0] years using the ilioinguinal approach) [1].

Mechanism of injury and surgical approaches

Most patients were injured in traffic accidents ($n = 184$) [1, 16, 17, 19, 20, 22, 23, 24, 25]. A fall from a height of >3 m caused a fracture in 108 patients [1, 16, 17, 19, 20, 22, 23, 24, 25], whereas a fall from a height of <3 m caused a fracture in 65 patients [1, 19, 23, 24, 25]. In 11 patients, the injury resulted from falling heavy objects [21, 23]. Sports injury has been reported in nine patients [21]. Figure 1 presents a diagram of the approach to the acetabulum, taking into account the mechanism of injury. The graph presents data from nine sources because the mechanism of injury is not mentioned in other works.

Classification of fractures and surgical approaches

In 11 studies, the nature of acetabular fractures was classified according to Judet-Letournel. Fracture of both columns was noted in four studies [1, 16, 22, 25]. Borg et al. and Ozturk et al. used Kocher-Langenbeck and ilioinguinal approaches [1, 25], Xue et al. used Kocher-Langenbeck and Pfannenstiel approaches [16], and Wang et al. used the pararectal approach to the anterior column [22] (Fig. 2).

Table 1

The use of surgical approaches and indications for surgery

Author	Observation period	Surgical approach	Number of patients	Age, years	Operative time, min.	Blood loss, ml
Borg T. [1]	2003–2014	Kocher-Langenbeck	16	76,5 (64–89)	188 (175–321)	800 (400–1700)
		Ilio-inguinal	10	68,2 (50–83)	166 (95–354)	675 (300–2600)
Harris A. [11]	1990–1998	Kocher-Langenbeck	51	34,9 (16–64)	320 (140–503)	1735 (300–4000)
Xue Z. [16]	2011–2012	Pfannenstiel	7	37 (18–53)	158,57±28,54	1057,14±377,96
		Kocher-Langenbeck	8	37 (18–53)	278,12±62,33	937,50±362,28
Khira Y. [17]	2009–2017	Kocher-Langenbeck	20	32,9 (21–58)	135±20 (120–160)	780±350 (500–1500)
Li Y. [18]	2013–2017	Kocher-Langenbeck	9	37±17,09	71,28±9,69	742,22±228,68
Lont T. [19]	2000–2017	Kocher-Langenbeck	34	70 (56–92)	169	1100
Kashyap S. [20]	2012–2015	Kocher-Langenbeck	30	48±24	215±55	570±160
Salameh M. [21]	2010–2017	Kocher-Langenbeck (decubitus)	47	36,6 (20–67)	184,2±57,5	551±299
		Kocher-Langenbeck (prone)	26	34,8 (18–60)	241,4±106,7	584±365
Wang C. [22]	2016–2017	prone	50	45,1±12,6	170,7±40,6	1177,1±691,6
Wang P. [23]	2013–2016	Ilio-inguinal	47	41,5±11,7	264,0±56,4	873,8±535,6
Yang Y. [24]	2014–2018	Ilio-inguinal	44	41,89±14,19	156,18±27,54	784,09±277,70
		Ilio-inguinal + Stoppa	32	39,94±15,21	126,53±29,56	625,31±193,39
Ozturk A. [25]	2017–2018	Kocher-Langenbeck	12	41,9	199,16±24,75	511,66±127,33
		Ilio-inguinal	5	46,2	200,00±25,49	488,00±111,89

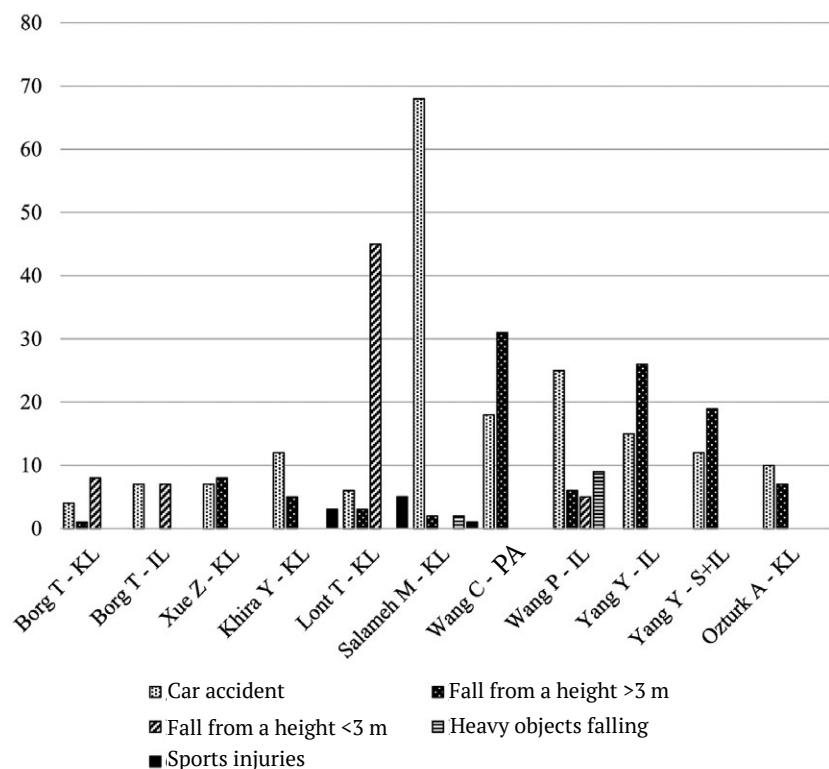


Fig. 1. The choice of approach to acetabulum depending on the mechanism of injury. Abbreviations hereafter: KL – Kocher-Langenbeck approach; IL – iliac-inguinal approach; S – Stoppa approach; PA – pararectal approach

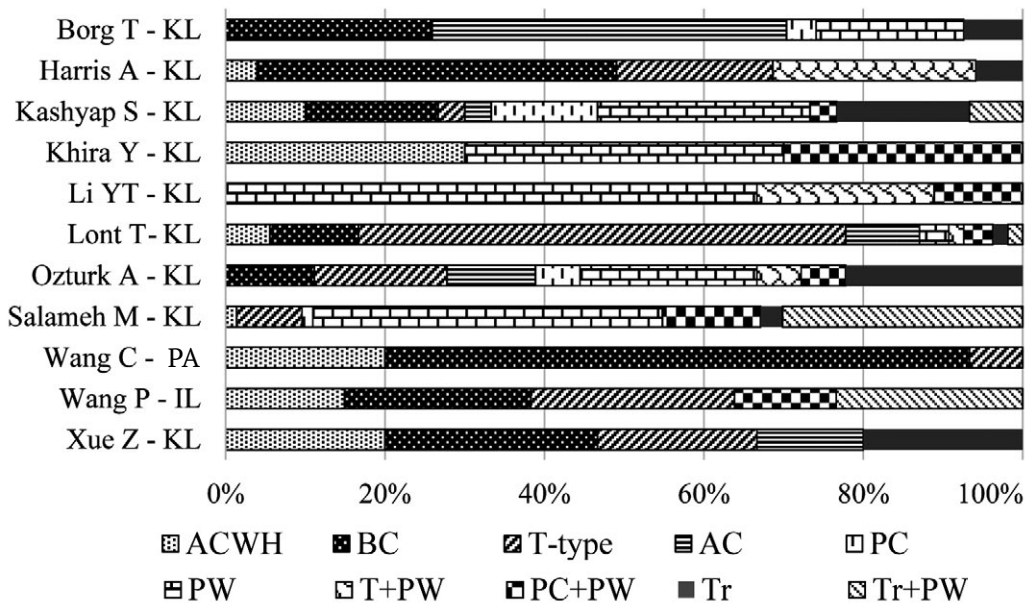


Fig. 2. Classification of acetabulum fractures according to Judet-Letournel in the cited sources. Percentages indicate the proportion of acetabulum fractures types from their total number

ACWH – fractures of the anterior column and hemitransverse fracture of the acetabulum posterior column; BC – fracture of both columns; T-type – T-shaped fracture; AC – fracture of the anterior column; PC – fracture of the posterior column; PW – fracture of the posterior wall; Tr – transverse acetabulum fracture

Fractures of the anterior column in combination with a semitransverse fracture of the posterior column of the acetabulum were recorded in 65 patients [1, 16, 19, 22, 23]. Fractures of the posterior wall were detected in 56 patients [1, 16, 17, 19, 21, 25]. A transverse fracture combined with a fracture of the posterior wall was found in 45 patients [1, 17, 19, 21, 23, 25], and a T-shaped fracture was registered in 36 patients [16, 19, 21, 22, 23, 25].

Operative time and blood loss depending on the surgical approach to the acetabulum

The indicators of operative time and blood loss during surgical intervention using various approaches in patients with acetabular fractures were analyzed in all 12 publications (Fig. 3).

Wang et al. performed surgery on 50 patients using the pararectal approach. A comparative analysis revealed that the pararectal approach required the shortest time (101.0±27.0 min) to perform surgery [22]. The longest time to perform the surgery using the ilioinguinal approach was noted in the study by Wang et al. (264.0±56.4 min) [23].

Wang et al. recorded blood loss of 1177.1±691.6 mL when using the pararectal approach [22]. The average blood loss volume was 844.8±368.8 mL in multi-authored publications using the Kocher-Langenbeck approach [1, 11, 16, 17, 18, 19, 20, 21]. When using the ilioinguinal approach, the average blood loss was 689.2±148.2 mL [1, 23, 24, 25].

Results of surgical treatment using the Kocher-Langenbeck approach in the prone and lateral positions

The authors of the cited sources analyzed the operative time and blood loss in 106 patients aged between 36.6 (20–67) and 47.2 (24–69) years [16, 18, 20, 21, 25] and 97 patients aged 32.9 between (21–58) and 34.9 (16–64) years [11, 18, 22] when performing the Kocher-Langenbeck surgical approach with the patients in the prone and lateral positions (Fig. 4). The surgical intervention with the patient in the lateral position allows the reduction of the operative time by 16.8% and blood loss by 12.4% in comparison with the prone position [17, 18, 19, 20, 21] (Fig. 4).

Results of the classic ilioinguinal and Stoppa's ilioinguinal approaches

Several authors analyzed the results of using the classic ilioinguinal approach (n=96, 128 cases) [23, 24, 25] and Stoppa's ilioinguinal approach (n=32) [24]. The mean age of the patients was

42.7±3.4 years (Fig. 5). The use of the modified Stoppa approach allows the reduction of the operative time by 40%. The blood loss volume was the greatest when using the classic ilioinguinal approach (828.9±63.4 mL). Less blood loss was recorded when using the modified Stoppa approach (625.3 mL).

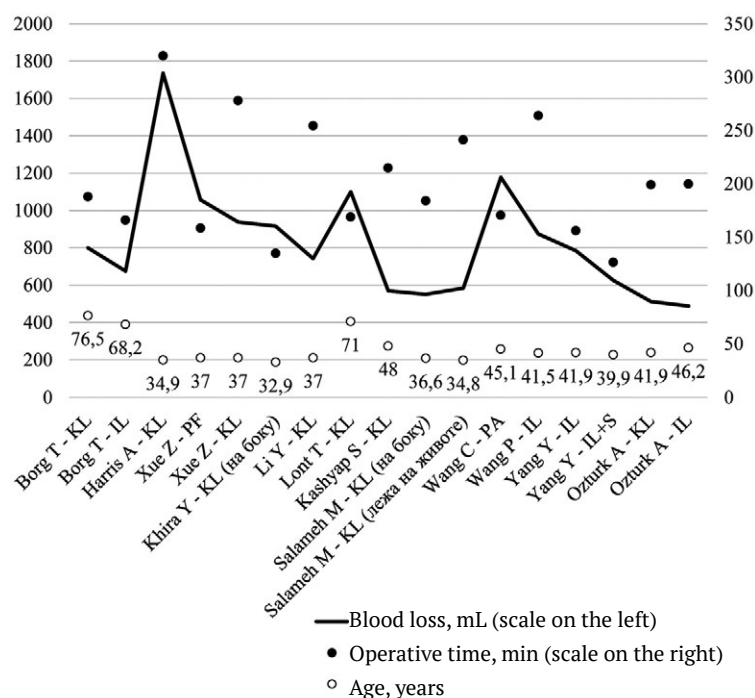


Fig. 3. Operative time, blood loss and the age of patients with various surgical approaches to the acetabulum

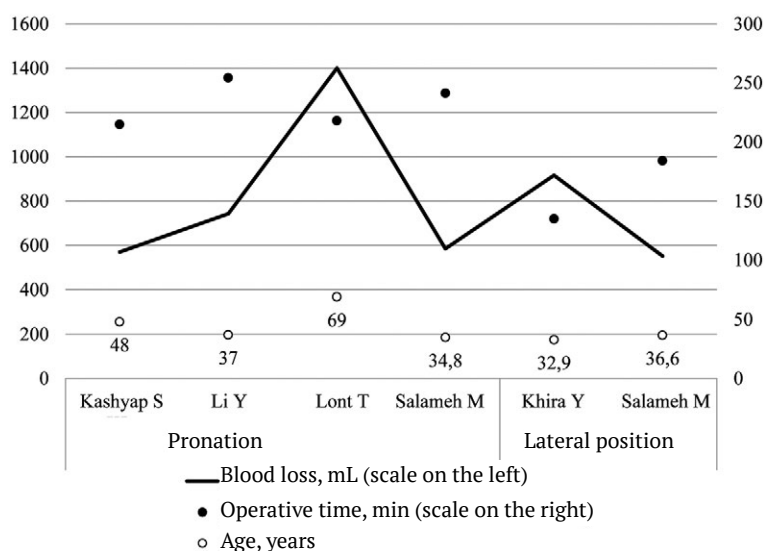


Fig. 4. Operative time, blood loss and the age of the patients during the surgery using the Kocher-Langenbeck approach in the supine position and lateral position

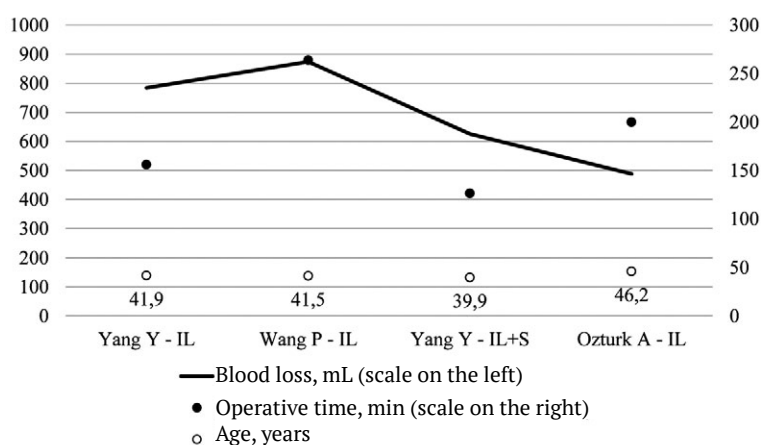


Fig. 5. Operative time, blood loss and the age of patients during surgery through the classical iliac-inguinal approach and iliac-inguinal approach in the Stoppa modification

DISCUSSION

As noted above, the choice of approach in the surgical treatment of acetabular fractures affects the operative time, blood loss, and treatment outcomes. In turn, the choice of approach is determined by various factors, such as the patient's age, fracture type, mechanism of injury, etc.

According to Giannoudis et al., the mean age of patients who underwent surgery for acetabular fractures was 38.6 ± 4.6 years, with men accounting for 69.4% [26]. Goyal et al. included patients with acetabular fractures aged >55 years, with a mean age of 72.5 years [14].

Acetabular fractures with a low-energy injury mechanism mainly occur in older patients. In young patients, a high-energy mechanism of injury is noted [6, 27, 28, 29, 30, 31, 32, 33].

In all publications the authors used the classification of acetabular fractures [developed by Judet and Letournel [33, 34]. Butler et al. indicated the fundamental significance and latent potentialities of this classification [35]. Letournel, the author of the classification, highlighted that the classification of acetabular fractures can be modified in relation to older patients [33, 34]. Some authors believe that the complexity of treatment of acetabular fractures in older patients is attributed to their fracture types, namely, more frequent fractures of the anterior acetabular column, quadrangular surface, and compression of the cartilage of the articular surface [6, 36, 37]. Goyal et al. noted that fractures of both columns are the most common fractures in their patients (19.03%), fractures of the anterior column in combination with a

semitransverse fracture of the posterior wall were less common (17.23%), fractures of the anterior column were registered in 541 of 3157 (17.13%) cases, and posterior wall fractures were noted in 425 of 3157 (13.46%) patients [14]. In younger patients, fractures of the posterior wall are more common, whereas transverse fractures of the acetabulum in combination with a fracture of the posterior wall and T-shaped fractures are less common [38, 39].

A literature analysis revealed that the blood loss depends on the approach, i.e., alone or in combination, and accordingly on operative time. The operative time between the Kocher-Langenbeck approach and the modified Stoppa approach was not significantly different. Moreover, the direct dependence of the blood loss on the operative time is expected as confirmed by other authors [26, 40, 41, 42].

Among 203 patients with acetabular fractures who underwent surgery using the Kocher-Langenbeck approach, surgeries were performed in 52.2% ($n = 106$) of cases with the patient in the lateral position, which reduced the operative time by 16.8% and blood loss by 12.4% in comparison with that in the prone position [17, 18, 20, 21]. In our opinion, the question of using the Kocher-Langenbeck approach in various positions on the operating table requires further study.

The ilioinguinal approach was used in 75% ($n = 96$) of cases, and the Stoppa ilioinguinal approach — in 25% ($n = 32$) of cases. According to the data obtained, Stoppa approach allows the reduction of operative time by 40% and blood loss by 11% compared with the classical ilioinguinal approach.

The authors of the analyzed publications used surgical approaches initially taking into account fractures of the acetabular columns (isolated and simultaneous fractures of the anterior and posterior columns) [43, 44, 45, 46]. In principle, in fractures of the anterior column and anterior wall of the acetabulum, the authors used the ilioinguinal or Stoppa approach [46, 47, 48, 49, 50, 51].

CONCLUSION

Comparative clinical studies are needed to determine the safest surgical approaches to the acetabulum depending on the fracture type, injury mechanism, and patient age.

DISCLAIMERS

Author contribution

Kolesnik A.I. — research concept and design, the collection and processing of material, writing the draft, editing.

Donchenko S.V. — research concept and design, the collection and processing of material, writing the draft, editing.

Surikov V.V. — the collection and processing of material, writing the draft, editing.

Ivanov D.A. — the collection and processing of material, writing the draft, editing.

Tarasov E.P. — the collection and processing of material, writing the draft, editing.

Yarmamedov D.M. — the collection and processing of material, writing the draft, editing.

Solodilov I.M. — the collection and processing of material, writing the draft, editing.

All authors have read and approved the final version of the manuscript of the article. All authors agree to bear responsibility for all aspects of the study to ensure proper consideration and resolution of all possible issues related to the correctness and reliability of any part of the work.

Funding source. This study was not supported by any external sources of funding.

Competing interests. The authors declare that they have no competing interests.

Ethics approval. Not applicable.

Consent for publication. Not required.

REFERENCES

1. Borg T., Hernefalk B., Hailer N.P. Acute total hip arthroplasty combined with internal fixation for displaced acetabular fractures in the elderly: a short-term comparison with internal fixation alone after a minimum of two years. *Bone Joint J.* 2019;101-B(4):478-483. doi: 10.1302/0301-620X.101B4.BJJ-2018-1027.R2.
2. Sardesai N.R., Miller M.A., Jauregui J.J., Griffith C.K., Henn R.F., Nascone J.W. Operative management of acetabulum fractures in the obese patient: challenges and solutions. *Orthop Res Rev.* 2017;9:75-81. doi: 10.2147/ORR.S113424.
3. Butterwick D., Papp S., Gofton W., Liew A., Beaulé P.E. Acetabular fractures in the elderly: evaluation and management. *J Bone Joint Surg Am.* 2015;97(9):758-768. doi: 10.2106/JBJS.N.01037.
4. Hoge S., Chauvin B.J. Acetabular Fractures. [Updated 2022 Mar 26]. In: StatPearls [Internet]. Treasure Island (FL): StatPearls Publishing; 2022 Jan. Available from: <https://www.ncbi.nlm.nih.gov/books/NBK544315/>.
5. Rommens P.M., Bastian J.D. Focus on acetabular fractures. *Eur J Trauma Emerg Surg.* 2021;47(5):1289-1290. doi: 10.1007/s00068-021-01766-1.
6. Mohan K., Broderick J.M., Raza H., O'Daly B., Leonard M. Acetabular fractures in the elderly: modern challenges and the role of conservative management. *Ir J Med Sci.* 2022;191(3):1223-1228. doi: 10.1007/s11845-021-02711-2.
7. Borrelli J.Jr., Anglen J.O. Acute Total Hip Arthroplasty for Fracture of the Acetabulum. In: *Arthroplasty for the Treatment of Fractures in the Older Patient.* Springer Nature; 2018. p. 129-144.
8. Cornell C.N. Management of acetabular fractures in the elderly patient. *HSS J.* 2005;1(1):25-30. doi: 10.1007/s11420-005-0101-7.
9. Russell G.V. Jr., Nork S.E., Chip Routt M.L. Jr. Perioperative complications associated with operative treatment of acetabular fractures. *J Trauma.* 2001;51(6):1098-1103. doi: 10.1097/00005373-200112000-00014.
10. Manson T.T. Open Reduction and Internal Fixation Plus Total Hip Arthroplasty for the Acute Treatment of Older Patients with Acetabular Fracture: Surgical Techniques. *Orthop Clin North Am.* 2020;51(1):13-26. doi: 10.1016/j.oocl.2019.08.006.
11. Harris A.M., Althausen P., Kellam J.F., Bosse M.J. Simultaneous anterior and posterior approaches for complex acetabular fractures. *J Orthop Trauma.* 2008;22(7):494-497. doi: 10.1097/BOT.0b013e3181830d2a.
12. Wu H., Shang R., Cai X., Liu X., Song C., Chen Y. Single Iliioinguinal Approach to Treat Complex Acetabular Fractures with Quadrilateral Plate Involvement: Outcomes Using a Novel Dynamic Anterior Plate-Screw System. *Orthop Surg.* 2020;12(2):488-497. doi: 10.1111/os.12648.
13. Swartman B., Pelzer J., Vetter S.Y., Beisemann N., Schnetzke M, Keil H. et al. Minimally invasive surgical treatment of minimally displaced acetabular fractures does not improve pain, mobility or quality of life compared to conservative treatment: a matched-pair analysis of 50 patients. *J Orthop Surg Res.* 2020;15(1):115. doi: 10.1186/s13018-020-01611-y.

14. Goyal T., Singh G., Kumar Tripathy S., Schuh A., Veerappa L.A., Kumar Sen R. Acetabulum fractures in elderly: A systematic review of fracture pattern and treatment. *J Clin Orthop Trauma*. 2020;11(6):989-1001. doi: 10.1016/j.jcot.2020.09.008.
15. Wollmerstädt J., Pieroh P., Schneider I., Zeidler S., Höch A., Josten C. et al. Mortality, complications and long-term functional outcome in elderly patients with fragility fractures of the acetabulum. *BMC Geriatr*. 2020;20(1):66. doi: 10.1186/s12877-020-1471-x.
16. Xue Z., Qin H., Ding H., An Z. A Novel Approach for Treatment of Acetabular Fractures. *Med Sci Monit*. 2016;22:3680-3688. doi: 10.12659/msm.898887.
17. Khira Y.M., El-Aidy S. Surgical treatment of marginal osteochondral impaction in acetabular fractures. *Musculoskelet Surg*. 2018;102(2):139-145. doi: 10.1007/s12306-017-0506-8.
18. Li Y.T., Hung C.C., Chou Y.C., Chen J.E., Wu C.C., Shen H.C. et al. Surgical Treatment for Posterior Dislocation of Hip Combined with Acetabular Fractures Using Preoperative Virtual Simulation and Three-Dimensional Printing Model-Assisted Precontoured Plate Fixation Techniques. *Biomed Res Int*. 2019;2019:3971571. doi: 10.1155/2019/3971571.
19. Lont T., Nieminen J., Reito A., Pakarinen T.K., Pajamäki I., Eskelinen A. et al. Total hip arthroplasty, combined with a reinforcement ring and posterior column plating for acetabular fractures in elderly patients: good outcome in 34 patients. *Acta Orthop*. 2019;90(3):275-280. doi: 10.1080/17453674.2019.1597325.
20. Kashyap S., Mahajan S., Lal M. Effects of topical tranexamic acid during open reduction and internal fixation of acetabular fractures: A retrospective study. *Acta Orthop Traumatol Turc*. 2019;53(3):175-179. doi: 10.1016/j.aott.2019.03.006.
21. Salameh M., Hammad M., Babikir E., Ahmed A.F., George B., Alhaneedi G. The role of patient positioning on the outcome of acetabular fractures fixation through the Kocher-Langenbeck approach. *Eur J Orthop Surg Traumatol*. 2021;31(3):503-509. doi: 10.1007/s00590-020-02793-1.
22. Wang C., Chen Y., Wang L., Wang D., Gu C., Lin X. et al. Three-dimensional printing of patient-specific plates for the treatment of acetabular fractures involving quadrilateral plate disruption. *BMC Musculoskelet Disord*. 2020;21(1):451. doi: 10.1186/s12891-020-03370-7.
23. Wang P., Kandemir U., Zhang B., Fei C., Zhuang Y., Zhang K. The effect of new preoperative preparation method compared to conventional method in complex acetabular fractures: minimum 2-year follow-up. *Arch Orthop Trauma Surg*. 2021;141(2):215-222. doi: 10.1007/s00402-020-03472-w.
24. Yang Y., Zou C., Fang Y. The Stoppa combined with iliac fossa approach for the treatment of both-column acetabular fractures. *J Orthop Surg Res*. 2020;15(1):588. doi: 10.1186/s13018-020-02133-3.
25. Öztürk A.M., Süer O., Şirintürk S., Aktuğlu K., Govsa F., Özer M.A. A retrospective comparison of the conventional versus three-dimensional printed model-assisted surgery in the treatment of acetabular fractures. *Acta Orthop Traumatol Turc*. 2020;54(4):385-393. doi: 10.5152/j.aott.2020.19054.
26. Giannoudis P.V., Grotz M.R., Papakostidis C., Dinopoulos H. Operative treatment of displaced fractures of the acetabulum. A meta-analysis. *J Bone Joint Surg Br*. 2005;87(1):2-9.
27. Ferguson T.A., Patel R., Bhandari M., Matta J.M. Fractures of the acetabulum in patients aged 60 years and older: an epidemiological and radiological study. *J Bone Joint Surg Br*. 2010;92(2):250-257. doi: 10.1302/0301-620X.92B2.22488.
28. Kim C.Y., Trivedi N.N., Sivasundaram L., Ochenjele G., Liu R., Vallier H. Predicting postoperative complications and mortality after acetabular surgery in the elderly: a comparison of risk stratification models. *Current Orthop Practice*. 2020;31(2):162-167. doi: 10.1097/BCO.0000000000000836.
29. Hasegawa I., Hasegawa M., Livingstone J.P., Kane T.J.K. 4th, Lee L. What's New in Geriatric Acetabular Fractures. *Hawaii J Health Soc Welf*. 2022;81(3 Suppl 1):19-24.
30. Rajagopal H.P., Mohan M.M., Kurian B.T., Ramesh L.J., Pilar A., Tamboowalla K.B. Functional outcome following conservative management of acetabular fractures. *Int J Res Orthop*. 2020;6(5):1027-1031. doi: 10.18203/issn.2455-4510.IntJResOrthop20203726.
31. Baker G., McMahon S.E., Warnock M., Johnston A., Cusick L.A. Outcomes of conservatively managed complex acetabular fractures in the frail and elderly one year post injury. *Injury*. 2020;51(2):347-351. doi: 10.1016/j.injury.2019.12.008.
32. Deren M.E., Babu J., Cohen E.M., Machan J., Born C.T., Hayda R. Increased Mortality in Elderly Patients with Sarcopenia and Acetabular Fractures. *J Bone Joint Surg Am*. 2017;99(3):200-206. doi: 10.2106/JBJS.16.00734.
33. Judet R., Judet J., Letournel E. Fractures of the acetabulum: classification and surgical approaches for open reduction. Preliminary report. *J Bone Joint Surg Am*. 1964;46:1615-1646.
34. Letournel E. Acetabulum fractures: classification and management. *Clin Orthop Relat Res*. 1980;(151):81-106.
35. Butler B.A., Lawton C.D., Hashmi S.Z., Stover M.D. The Relevance of the Judet and Letournel Acetabular Fracture Classification System in the Modern Era: A Review. *J Orthop Trauma*. 2019;33 Suppl 2:S3-S7. doi: 10.1097/BOT.0000000000001401.
36. Bible J.E., Wegner A., McClure D.J., Kadakia R.J., Richards J.E., Bauer J.M. et al. One-year mortality after acetabular fractures in elderly patients presenting to a level-1 trauma center. *J Orthop Trauma*. 2014;28(3):154-159. doi: 10.1097/BOT.0b013e31829e801b.
37. Herath S.C., Pott H., Rollmann M.F.R., Braun B.J., Holstein J.H., Höch A. et al. Geriatric Acetabular Surgery: Letournel's Contraindications Then and Now-Data From the German Pelvic Registry. *J Orthop Trauma*. 2019;33 Suppl 2:S8-S13. doi: 10.1097/BOT.0000000000001406.
38. Mauffrey C., Hao J., Cuellar D.O. 3rd, Herbert B., Chen X., Liu B. et al. The epidemiology and injury patterns of acetabular fractures: are the USA and China comparable? *Clin Orthop Relat Res*. 2014;472(11):3332-3337. doi: 10.1007/s11999-014-3462-8.
39. Cavalcante M.C., de Arruda F.A.A., Boni G., Sanchez G.T., Balbachevsky D., Dos Reis F.B. Demographic analysis of acetabular fractures treated in a quaternary care hospital from 2005 to 2016. *Acta Ortop Bras*. 2019;27(6):317-320. doi: 10.1590/1413-785220192706207042.

40. Letournel E., Judet R. Fractures of the Acetabulum. Berlin, Germany: Springer-Verlag; 1993. p. 375-385; 521-540; 591-633.
41. Shazar N., Eshed I., Ackshota N., Hershkovich O., Khazanov A., Herman A. Comparison of acetabular fracture reduction quality by the ilioinguinal or the anterior intrapelvic (modified Rives-Stoppa) surgical approaches. *J Orthop Trauma*. 2014;28(6):313-319. doi: 10.1097/01.bot.0000435627.56658.53.
42. Negrin L.L., Seligson D. Results of 167 consecutive cases of acetabular fractures using the Kocher-Langenbeck approach: a case series. *J Orthop Surg Res*. 2017;12(1):66. doi: 10.1186/s13018-017-0563-6.
43. Matta J.M. Operative treatment of acetabular fractures through the ilioinguinal approach. A 10-year perspective. *Clin Orthop Relat Res*. 1994;(305):10-19.
44. Matta J.M. Fractures of the acetabulum: accuracy of reduction and clinical results in patients managed operatively within three weeks after the injury. *J Bone Joint Surg Am*. 1996;78(11):1632-1645.
45. Kloen P., Siebenrock K.A., Ganz R. Modification of the ilioinguinal approach. *J Orthop Trauma*. 2002;16(8):586-593. doi: 10.1097/00005131-200209000-00008.
46. Cole J.D., Bolhofner B.R. Acetabular fracture fixation via a modified Stoppa limited intrapelvic approach. Description of operative technique and preliminary treatment results. *Clin Orthop Relat Res*. 1994;(305):112-123.
47. Gao Y.S., Zhou Z.B., Tang M.J., Yu X.W., Chen S., Zhang C.Q. et al. Late surgery for acetabular fractures in a Chinese level I trauma centre: surgical experience and outcomes. *Int Orthop*. 2015;39(9):1865-1871. doi: 10.1007/s00264-015-2932-2.
48. Rickman M., Young J., Bircher M., Pearce R., Hamilton M. The management of complex acetabular fractures in the elderly with fracture fixation and primary total hip replacement. *Eur J Trauma Emerg Surg*. 2012;38(5):511-516. doi: 10.1007/s00068-012-0231-9.
49. Yang Y., Li Q., Cui H., Hao Z., Wang Y., Liu J. et al. Modified Ilioinguinal Approach to Treat Pelvic or Acetabular Fractures: A Retrospective Study. *Medicine (Baltimore)*. 2015;94(37):e1491. doi: 10.1097/MD.0000000000001491.
50. Jakob M., Drosler R., Zobrist R., Messmer P., Regazzoni P. A less invasive anterior intrapelvic approach for the treatment of acetabular fractures and pelvic ring injuries. *J Trauma*. 2006;60(6):1364-1370. doi: 10.1097/01.ta.0000208139.97474.f7.
51. Andersen R.C., O'Toole R.V., Nascone J.W., Sciadini M.F., Frisch H.M., Turen C.W. Modified Stoppa approach for acetabular fractures with anterior and posterior column displacement: quantification of radiographic reduction and analysis of interobserver variability. *J Orthop Trauma*. 2010;24(5):271-278. doi: 10.1097/BOT.0b013e3181b2b4ca.

Authors' information

✉ Alexander I. Kolesnik — Dr. Sci. (Med.), Professor
Address: 24, Onezhskaya str., Moscow, 125413, Russia
<https://orcid.org/0000-0003-1435-8743>
e-mail: ko-lesnik@mail.ru

Sergey V. Donchenko — Cand. Sci. (Med.)
<https://orcid.org/0000-0003-3341-7446>
e-mail: Don_03@mail.ru

Vladislav V. Surikov
<https://orcid.org/0000-0003-3668-2376>
e-mail : Airbag366@yandex.ru

Dmitry A. Ivanov
<https://orcid.org/0000-0002-5821-6774>
e-mail : Ivanovda2001@mail.ru

Evgeniy P. Tarasov
<https://orcid.org/0000-0002-3960-0148>
e-mail: t.john@mail.ru

Dmitry M. Yarmamedov
<https://orcid.org/0000-0002-4580-5502>
e-mail: D-yarmamedov@mail.ru

Ivan M. Solodilov — Cand. Sci. (Med.)
<https://orcid.org/0000-0001-8219-5582>
e-mail: Ivan_s_007@mail.ru